



Familial Primary Open Angle Glaucoma

Priyanka Patel ^{a*}, Prabha Sonwani ^{a#} and Suchita Singh ^{a‡}

^a Department of Ophthalmology, Chhattisgarh Institute of Medical Sciences, Bilaspur, C.G., India.

Authors' contributions

This work was carried out in collaboration among all authors. All authors read and approved the final manuscript.

Article Information

DOI: 10.9734/OR/2022/v16i430242

Open Peer Review History:

This journal follows the Advanced Open Peer Review policy. Identity of the Reviewers, Editor(s) and additional Reviewers, peer review comments, different versions of the manuscript, comments of the editors, etc are available here: <https://www.sdiarticle5.com/review-history/88545>

Case Study

Received 01 May 2022
Accepted 09 July 2022
Published 13 July 2022

ABSTRACT

Primary open-angle glaucoma (POAG), also known as chronic simple glaucoma, is usually an inherited disease. Inheritance is considered multifunctional and polygenic. Glaucoma is the second leading cause of irreversible blindness worldwide, of which POAG is the most common. First-degree relatives of POAG patients are at increased risk. A reasonable risk for siblings is four and twice the risk of the normal population for the offspring, although the number of surveys varies. This case series of eight family members with POAG illustrates the stealth nature of POAG and the devastating vision loss it can cause as it progresses; emphasizing regular and comprehensive eye examinations during its early stage.

Keywords: Hereditary; POAG; intraocular pressure; cup: disc ratio; gonioscopy; autosomal dominant.

1. INTRODUCTION

Glaucoma is the second leading cause of irreversible blindness worldwide, of which POAG accounts for a major three-quarter (74%) of all glaucoma cases [1]. POAG represents a complex, multifactorial trait with a substantial fraction exhibiting a significant heritability [2].

Less than 10% of POAG cases in the general population are caused by specific gene mutations and the remaining cases are polygenic [2]. Quantitative traits related to POAG pathogenesis such as intraocular pressure (IOP), vertical cup/disc ratio (CDR), optic disc area, and central corneal thickness (CCT) are highly heritable, and likely to be influenced at least in

*PG Resident;

#Assistant Professor;

‡Associate professor;

*Corresponding author: E-mail: pp758209@gmail.com;

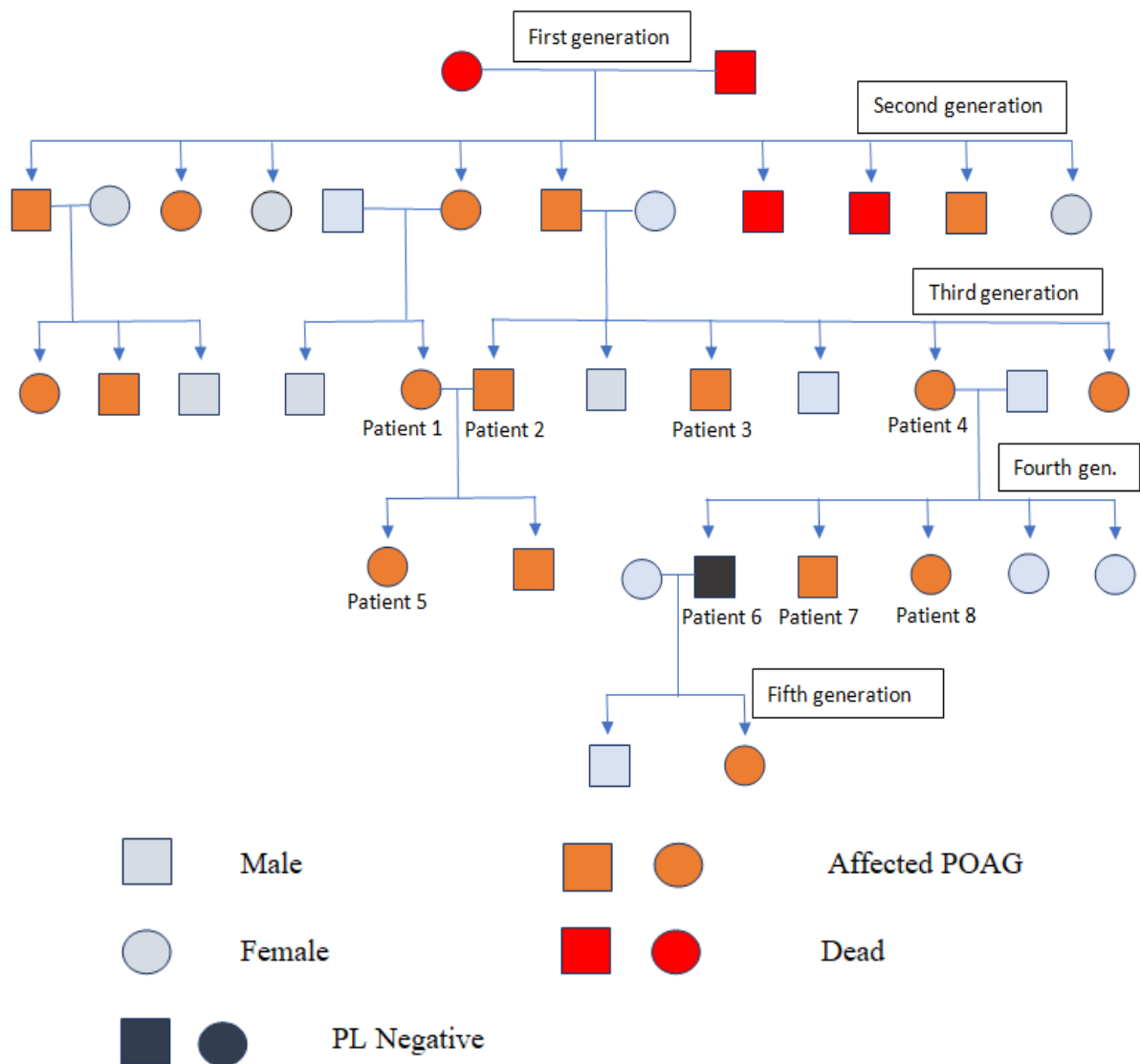
part by genes and show substantial variation in human populations [2].

Recent advances in genomic technologies and genome-wide association studies (GWAS) have greatly accelerated the discovery and understanding of genes and genomic regions associated with POAG and influencing the quantitative endophenotype traits related to POAG pathogenesis [2]. Genetic linkage studies of large affected families have till now identified at least 20 chromosomal loci (GLC1A-P) that are linked to POAG. The suspected causative genes that are capable of causing POAG to include myocilin (*MYOC*), optineurin (*OPTN*), WD repeat domain 36 (*WDR36*), ankyrin repeat, and SOCS-box containing 10 (*ASB10*), Cytochrome P450

family 1, subtype B, polypeptide 1 (*CYP1B1*), and Neurotrophin 4 (*NTF4*) [3,4].

In this study, we present clinical data of eight family members who visited the outpatient department of CIMS Bilaspur Medical College, with complaints of progressive decrease in visual acuity and dull eye ache. All eight individuals had comprehensive eye examination including visual acuity testing, slit-lamp biomicroscopy, indentation tonometry, gonioscopy, and fundus examination after which the diagnosis of familial POAG was made. The presented patients belong to a joint family with a history of consanguineous marriage consisting of five generations of a total of 32 members, 18 of whom are affected by POAG.

The pedigree chart of the family:



Total of eighteen members affected were screened and distributed by the local clinician and ophthalmic assistants, eight members of third and fourth generation were brought to CIMS Bilaspur C.G., five patients of second and fifth-generation were taken to government medical college Raipur C.G. and five members of second, third and fourth generation were taken to government medical college Raigarh C.G.

2. CASE DESCRIPTION

Patient 1: A 30 years old female (third generation in the family) consulted for constant dull eye ache and seeing of colored halos in both eyes for 6 months, was diagnosed with POAG in both eyes at the age of 17 years, had a history of trabeculectomy of both eyes performed at the age of 17 years and she is instilling eyedrop Dorzolamide with timolol combination since then.

Patient 2: A 45-year-old male (third generation in the family) consulted for headache, dull eye ache, and photophobia in both eyes for 6 months, was diagnosed as POAG at age of 25 and is using Dorzolamide eye drop and Brimonidine Tartrate with Timolol combination eye drop since then.

Patient 3: A 22-year-old male (third generation in the family) consulted for headache, dull eye ache, and diminution of vision in both eyes, was diagnosed with POAG in the right eye 4 months ago and in the left eye 2 months ago, had a trabeculectomy of the right eye 2 months back. He is instilling eye drop Timolol in right eye for 4 months and in left eye for 2 months.

Patient 4: A 40 years old female (third generation in the family) consulted for constant dull eye ache in both eyes, was diagnosed with POAG 17 years back, had trabeculectomy of both eyes 16 years back and is instilling Timolol eyedrop since then.

Patient 5: 17 years old female (fourth generation in the family) consulted for headache, dull eye ache, deviation of the right eye, and diminution of vision in both eyes since childhood. She was diagnosed with congenital ptosis in her right eye 5 years ago and a frontalis sling operation was done 5 years ago. She was diagnosed with juvenile glaucoma in both eyes 3 years ago and is instilling Dorzolamide and Brimonidine Tartrate with Timolol combination eye drops.

Patient 6: A 25 years old male (fourth generation in the family) consulted with dull eye ache and decreased vision in both eyes and colored halos

in the left eye for 5 years, POAG was diagnosed in both eyes 5 years back and a trabeculectomy of the right eye was performed 4 years ago. He has had no perception of light in his right eye for 2 years. He is instilling eye drops Timolol and Travoprost eye in both eyes for 4 years.

Patient 7: A 23 years old male (fourth generation in the family) consulted with headache and dull eye ache in both eyes for 3years, was diagnosed POAG 3 years back. He is instilling eye drops Timolol in both eyes for 3 years.

Patient 8: A 17 years old girl (fourth generation in the family) consulted with headache and blurring of vision in both eyes for 1 year but is not receiving any treatment at present.

The four deceased members of the family (2 members of the first and 2 members of the second generation) were also having POAG, they were diagnosed at the age of 40, 41, 35, and 30 years respectively. The affected members of second generation were diagnosed with POAG between the age group 30 to 45 years whereas the affected members of the third generation were diagnosed with POAG between the age group of 20 to 40 years. The affected members of fourth generation were diagnosed between the age group of 15 to 25 years while the affected member of fifth generation was diagnosed at the age of 15 years.

At the time the members of first and second generation were diagnosed, the disease was already at the advanced stage and very little could be done to save their vision. But looking at the devastating vision loss caused by this disease and suspecting the role of inheritance, the successive generations were quick to receive treatment as soon as they were diagnosed and also showed good compliance with proper adherence to follow-up.

3. DISCUSSION

Prior studies [5,6,7] have established that primary open-angle glaucoma is more likely to affect persons with a family history of the disease. A proportion of POAG is known to have a genetic origin as demonstrated by family pedigrees conforming to dominant and recessive modes of Mendelian inheritance [8,9]. First-degree relatives of POAG patients are at increased risk. A reasonable risk for siblings is four and twice the risk of the normal population for the offspring, although the number of surveys varies.

Table 1. Clinical profile of the patients who presented to CIMS, Bilaspur (C.G.)

	Age in years	UCVA	BCVA	Right eye (Positive finding)	Left eye (Positive finding)	Intraocular pressure mmHg	Gonioscopy	Fundus	Probable diagnosis
Patient 1	30	OD– 6/36 OS – 6/24	OD– - 0.75/- 0.5/60°, 6/6 OS – 0.5/- 0.5/60°, 6/6	Iridectomy at 12 o'clock, superiorly conjunctival bleb present	Iridectomy at 12 o'clock, superiorly conjunctival bleb present	OD – 17.5 OS – 17.5	(BE) grade 4 in all quadrants	(BE) media clear, cup: disc ratio 0.6, foveal reflex dull, blood vessels appear normal	(BE) POAG
Patient 2	45	OD – 6/9 OS – 6/12	OD – -0.5 DS/10°, 6/6 OS – -0.25/-0.5/30°, 6/6	Within normal limit	Within normal limit	OD - 17.5 OS - 29.0	(BE) Grade 4 in all quadrants	(BE)- media clear, cup: disc ratio 0.5, neuroretinal rim, foveal reflex dull, blood vessels appear normal	(BE) POAG
Patient 3	22	OD– 4/60 OS – 6/6	OD – no improvement with glasses	Iridectomy at 12 o'clock, superiorly conjunctival bleb present	Within normal limit	OD - 22.4 OS - 17.3	(BE) grade 4 in all quadrants	(OD) – media clear, neuroretinal rim intact, cup: disc ratio 0.6, foveal reflex, blood vessels appear normal (OS) – Cup: disc ratio 0.4	(BE) POAG
Patient 4	40	OD – 6/36 OS – 6/60	No improvement with glasses	Iridectomy at 12 o'clock, superiorly conjunctival bleb present	Iridectomy at 12 o'clock, superiorly conjunctival bleb present	OD – 20.6 OS – 20.6	(BE) grade 4 in all quadrants	(BE) media clear, cup: disc ratio 0.6, peripapillary degeneration, foveal reflex dull, blood vessels appear normal	(BE) POAG
Patient 5	17	OD – 6/24 OS – 6/60	OD- -0.5/-0.5, 10° (6/6) OS- -14.0/-2.0, 35° (6/6)	Severe congenital ptosis with poor levator function, rest within normal limit	45 exotropia, Eyeball movement restricted in upward gaze, Rest within the normal limit	OD- 28.0 OS- 30.4	(BE) grade 4 in all quadrants	OD- media clear, cup: disc ratio 0.6, neuroretinal rim intact, foveal reflex present, blood vessels appear normal OS- myopic fundus	(OD) congenital ptosis (BE) POAG The patient was advised for surgery but the patient's parents were not willing to the surgery due to a poor visual prognosis

	Age in years	UCVA	BCVA	Right eye (Positive finding)	Left eye (Positive finding)	Intraocular pressure mmHg	Gonioscopy	Fundus	Probable diagnosis
Patient 6	25	OD- PL Negative OS – 6/18	(BE) – no improvement with glasses	Mild conjunctival congestion, Corneal edema present, Iridectomy at 12 o'clock, superiorly conjunctival bleb present	Mild conjunctival congestion, Rest finding within normal limit	OD – 7.1 OS – 18.9	(BE) – grade 4 in all quadrants	(BE)- media clear, total glaucomatous optic atrophy, blood vessels appear attenuated	(BE) POAG
Patient 7	23	OD – 6/18 OS – 6/12 With pinhole (BE)– 6/12	OD- -0.5 DS, 6/12 OS- no improvement	Conjunctival congestion, Rest findings within normal limit	Conjunctival congestion, Rest findings within normal limit	OD- 25.8 OS- 25.8	(BE) – grade 4 in all quadrants	(BE) – media clear, Cup : disc ratio 0.5, neuroretinal rim intact, foveal reflex bright, blood vessels appear normal	(BE) POAG
Patient 8	17	OD – 6/12 OS – 6/6	OD- +0.25 DS, 90°, 6/6 OS- no improvement	Within normal limit	Within normal limit	OD- 21.9 OS- 21.9	(BE) – grade 4 in all quadrants	(BE)- media clear, cup: disc ratio 0.5, neuroretinal rim intact, foveal reflex bright, blood vessels appear normal	(BE) POAG

*OD = right eye; OS = left eye; BE = both eye; UCVA = uncorrected visual acuity; BCVA = best corrected visual acuity

In our study, a family has five generations consisting of 32 members of which 16 are male and 14 are female. 18 family members were affected and out of these, eight members who presented to our setting were included in this study. The age of diagnosis among eight patients was between 14 and 25 years, which is considered juvenile POAG. All the patients had a common complaint of a mild headache, dull eye ache, and progressive diminution of vision. Gonioscopy examination of all the patients showed normal appearance and open anterior chamber angle without peripheral anterior synechiae. Each and every patient is under medical therapy since the day of diagnosis, resulting in good intraocular pressure control. Each member accepted timely treatment with high compliance and showed punctuality in their follow-up visits. Due to early diagnosis, proper treatment could be given at the proper time in the form of filtration surgery or medical management as per requirement. On follow-up visit examinations no patient showed any progression of glaucomatous changes. Genetic analysis revealed that the inheritance pattern of POAG in this family is autosomal dominant.

K. Shi et al. [10] in 2014 we report a case of POAG in a Chinese family consisting of 4 generations of 22 people (14 male and 8 female)

in this family. Eight POAG patients were identified, including the proband and her grandmother, father, aunt, eldest brother, second elder brother, cousin, and niece. The age at diagnosis (alive) was between 13 and 35 years (26.3 ± 2.8 years), which is considered juvenile POAG. Collectively, their visual field impairments were mostly early or metaphase-related, and the IOP ranged from 25.81 to 38.80 mmHg (32.51 ± 4.45 mmHg). Their prognoses were satisfactory after undergoing an operation or receiving medication.

Owing to pathologically elevated IOP, POAG manifests as an acquired optic nerve pit and visual field defect with open anterior chamber angle. Previous studies found that 13- 47% of POAG patients have a positive family history; [11] nevertheless, there is no consensus regarding the method by which POAG is inherited. It has been acknowledged that the inheritance pattern can be autosomal dominant, autosomal recessive, and multifactorial [12]. Typical POAG is not difficult to diagnose; however, since POAG onset is insidious and progresses slowly, most patients present to the clinic with irreversible optic nerve damage. Hence, early POAG diagnosis is one of the most challenging aspects of current ophthalmological clinical work [10].

Table 2. Age and sex predilection of the patients presenting to CIMS, Bilaspur

Patient	Age of diagnosis (years)	Sex
1	17	Female
2	25	Male
3	22	Female
4	23	Male
5	15	Male
6	21	Female
7	20	Male
8	16	Female

Male: Female (4:4 of presenting patients) = 1:1

Table 3. Number of patients (out of 8 presenting patients) requiring Trabeculectomy operation

Patient number	Age at which operation was performed	OD	OS
1	17	Iridectomy at 12 o'clock, superiorly conjunctival bleb present	Iridectomy at 12 o'clock, superiorly conjunctival bleb present
3	22	Iridectomy at 12 o'clock, superiorly conjunctival bleb present	
4	23	Iridectomy at 12 o'clock, superiorly conjunctival bleb present	Iridectomy at 12 o'clock, superiorly conjunctival bleb present
6	25	Iridectomy at 12 o'clock, superiorly conjunctival bleb present	

4. CONCLUSION

The genetic traits suggesting autosomal dominant type of inheritance in this familial POAG were:

1. Atavism was not present in this family since POAG patients were found in each generation.
2. The incidence of POAG is equal in both male and female patients.
3. If any of the parents were affected, their offspring were also affected.
4. The family had a history of consanguineous marriages.
5. Since there is a known family history and every family member should be made aware about the devastating nature of the disease especially the young generation.

INFERENCE

1. Break In the consanguinity is a must to decrease the incidence.
2. Early and regular ophthalmic screening of upcoming generations, starting from the age of 5 years
3. Regular follow-up of the patients

CONSENT

As per international standard or university standard, patients' written consent has been collected and preserved by the author(s).

ETHICAL APPROVAL

As per international standard or university standard written ethical approval has been collected and preserved by the author(s).

COMPETING INTERESTS

Authors have declared that no competing interests exist.

REFERENCES

1. Quigley HA, Broman AT. The number of people with glaucoma worldwide in 2010 and 2020. *Br. J. Ophthalmology*. 2006; 90:262–267. DOI: 10.1136/bjo.2005.081224. [PMC free article] [PubMed] [CrossRef] [Google Scholar]
2. Khaled Abu-Amero, Altaf A Kondkar, Kakarla V Chalam. An Updated Review on

the Genetics of Primary Open Angle Glaucoma. *International Journal of Molecular Sciences*. 2015 Dec;16(12): 28886–28911.

DOI: 10.3390/ijms161226135. [PMC free article] [PubMed] [CrossRef] [Google Scholar]

3. Janssen SF, Gorgels TG, Ramdas WD, Klaver CC, van Duijn CM, Jansonius NM, Bergen AA. The vast complexity of primary open angle glaucoma: Disease genes, risks, molecular mechanisms and pathobiology. *Prog. Retin Eye Res*. 2013;37:31–67.

DOI: 10.1016/j.preteyeres.2013.09.001. [PubMed] [CrossRef] [Google Scholar]

4. Takamoto M, Araie M. Genetics of primary open angle glaucoma. *Jpn. J. Ophthalmol*. 2014;58:1–15.

DOI: 10.1007/s10384-013-0286-0. [PubMed] [CrossRef] [Google Scholar]

5. Tielsch JM, Katz J, Sommer A, Quigley HA, Javitt JC. Family history and risk of primary open-angle glaucoma. The Baltimore Eye Survey. *Arch Ophthalmol*. 1994 Jan;112(1):69–73. [PubMed] [Google Scholar]

6. Nemesure B, Leske MC, He Q, Mendell N. Analyses of reported family history of glaucoma: A preliminary investigation. The Barbados Eye Study Group. *Ophthalmic Epidemiol*. 1996 Dec;3(3):135–141. [PubMed] [Google Scholar]

7. Leighton DA. Survey of the first-degree relatives of glaucoma patients. *Trans Ophthalmol Soc. UK*. 1976 Apr;96(1):28–32. [PubMed] [Google Scholar]

8. Posner A, Schlossman A. Role of inheritance in glaucoma. *Arch Ophthalmol*. 1949 Feb;41(2):125–150. [PubMed] [Google Scholar]

9. Francois J. Genetics and primary open-angle glaucoma. *Am J Ophthalmol*. 1966 Apr;61(4):652–665. [PubMed] [Google Scholar]

10. Shi K, Zhao L, Wang CY. Case report: familial primary open-angle glaucoma. *Genetics and molecular research*; 2014.

DOI: 10.4238/2014.April.17.12. [PubMed] [Google Scholar]

11. Gemenetzi M, Yang Y, Lotery AJ. Current concepts on primary open-angle glaucoma

- genetics: A contribution to disease pathophysiology and future treatment. Eye (Lond). 2012;26:355-369. [PubMed] [Google Scholar]
12. Allingham RR, Liu Y, Rhee DJ. The genetics of primary open-angle glaucoma: A review. Exp. Eye Res. 2009;88:837-844. [PubMed] [Google Scholar]

© 2022 Patel et al.; This is an Open Access article distributed under the terms of the Creative Commons Attribution License (<http://creativecommons.org/licenses/by/4.0>), which permits unrestricted use, distribution, and reproduction in any medium, provided the original work is properly cited.

Peer-review history:
The peer review history for this paper can be accessed here:
<https://www.sdiarticle5.com/review-history/88545>