



## Central Retinal Vein Occlusion Secondary to Paroxysmal Nocturnal Hemoglobinuria

Thiago Sande Miguel <sup>a</sup>, Ermes Rodrigues Machado Filho <sup>a</sup>,  
Bruna Sande Miguel <sup>b</sup>, Daniel Almeida da Costa <sup>c\*</sup>  
and Maurício Bastos Pereira <sup>a</sup>

<sup>a</sup> Universidade Federal Fluminense, Brazil.

<sup>b</sup> Faculdade do Grande Rio (UNIGRANRIO), Brazil.

<sup>c</sup> Centro Universitário de Valença, Brazil.

### Authors' contributions

*This work was carried out in collaboration among all authors. All authors read and approved the final manuscript.*

### Article Information

DOI: 10.9734/OR/2022/v16i330234

### Open Peer Review History:

This journal follows the Advanced Open Peer Review policy. Identity of the Reviewers, Editor(s) and additional Reviewers, peer review comments, different versions of the manuscript, comments of the editors, etc are available here: <https://www.sdiarticle5.com/review-history/87209>

Case Study

Received 12 March 2022

Accepted 23 May 2022

Published 27 May 2022

### ABSTRACT

**Aims:** To describe a Central Retinal Vein Occlusion Secondary to Paroxysmal Nocturnal Hemoglobinuria.

**Presentation of Case:** A 25 years old, male, student, in regular follow-up in the Hematology sector due to Paroxysmal Nocturnal Hemoglobinuria in regular use of Eculizumab. He reports a month ago that he suddenly noticed, upon waking up in the morning, blurring and decreased visual acuity in her left eye.

**Discussion:** Paroxysmal nocturnal hemoglobinuria (PNH) is an acquired disorder characterized by hemolysis, thrombosis, and bone marrow failure caused by defective expression of glycosylphosphatidylinositol-anchored (GPI-anchored) complement inhibitors. Most commonly, PNH is caused by the loss of PIGA function, which is necessary for GPI biosynthesis.

**Conclusions:** Patients with hemolytic anemia, unexplained thrombosis, especially in uncommon sites, cytopenias and bone marrow failure syndromes, dysphagia, and unexplained abdominal pain should be screened for PNH. PNH patients can benefit greatly from the treatments available, with a reduction in the risk of serious sequelae and a considerable improvement in their quality of life. So that the patient continues to be followed up in the ophthalmology department, with decreased visual acuity ipsilateral to the lesion, with a relative afferent pupillary defect on that side.

\*Corresponding author: E-mail: [daniel.almeida@faa.edu.br](mailto:daniel.almeida@faa.edu.br);

**Keywords:** *Thrombosis; anemia; paroxysmal nocturnal hemoglobinuria; retinal central vein occlusion; complement system; eculizumab.*

## 1. INTRODUCTION

“Paroxysmal nocturnal hemoglobinuria (PNH) is a clonal hematopoietic stem cell disorder that manifests with hemolytic anemia, bone marrow failure, and thrombosis” [1-4].

Hemolysis in PNH is complement-mediated and is a direct result of the acquisition of a deficiency in complement regulatory proteins by PNH cells. The disease begins with the expansion of a hematopoietic stem cell that has a severe deficiency or absence of glycosylphosphatidylinositol (GPI). GPI deficiency in virtually all PNH cases is the result of a somatic mutation in class A phosphatidylinositol glycan (PIGA), resulting in a deficiency of complement inhibitor proteins CD55 and CD59, which leads to complement-mediated chronic hemolysis of GPI-deficient erythrocytes, as well as the activation of platelets, monocytes and granulocytes [1,3-7].

“There are three main categories of PNH: (1) classic PNH, which includes hemolytic and thrombotic patients; (2) PNH in the context of other primary bone marrow diseases, such as aplastic anemia or myelodysplastic syndrome; and (3) subclinical PNH, in which patients have small PNH clones but no clinical or laboratory evidence of hemolysis or thrombosis” [2,3,5,8].

“Anemia in PNH is often multifactorial and may result from a combination of hemolysis and bone marrow failure. Intravascular hemolysis with moderate to severe anemia, elevated reticulocyte count, and up to a 10-fold increase in lactate dehydrogenase (LDH) is common in classic PNH” [2,4,6,8,9]. “Anemia in these patients is mainly due to bone marrow failure. Patients with subclinical PNH are, by definition, asymptomatic, with normal or near-normal blood counts and few granulocytes (<10%)” [2,4,6,7,10].

“Abdominal pain, esophageal spasm, dysphagia, and erectile dysfunction are common symptoms associated with classic PNH and are a direct consequence of intravascular hemolysis and the release of free hemoglobin” [5,8,10,11].

The absence of GPI-anchored complement regulatory proteins (CD55 and CD59) on PNH platelets leads to prothrombotic microparticles.

High levels of free hemoglobin lead to the elimination of nitric oxide (NO), which has been implicated in contributing to platelet activation and aggregation” [7,9,11-14]. “Complement activation also contributes to the prothrombotic tendency of PNH patients. Therefore, proinflammatory and prothrombotic states generating inflammatory cytokines such as interleukin-6, interleukin-8 and tumor necrosis factor- $\alpha$  contribute to the thrombophilic state in PNH [8,10,12-16].

“Complement inhibition is the most effective strategy to stop thrombosis in PNH. Thrombosis can occur in any patient with PNH, but those with a high percentage of PNH cells (>50% granulocytes) are at greatest risk” [7,9,13-18].

“Thrombosis causes severe morbidity and is the most common cause of mortality in PNH. Thrombosis in PNH can occur anywhere, and venous thrombosis is more common than arterial. The most common sites of thrombosis include intra-abdominal and cerebral veins. Retinal thrombotic events are very rare” [5,11,13,15].

“Thrombotic events and anticoagulation are indications for eculizumab. However, primary prophylactic anticoagulation was not shown to be beneficial in PNH. Furthermore, it is unclear whether uninterrupted anticoagulation is required for secondary prophylaxis in PNH patients who are well controlled on eculizumab” [4,9,19-22].

Eculizumab is a humanized monoclonal antibody that blocks terminal complement by binding to C5 and is the only approved therapy for PNH. This drug is highly effective in stopping intravascular hemolysis, eliminating or reducing the need for red blood cell transfusions, improving quality of life and reducing the risk of thrombosis, the main cause of mortality from PNH, and is used in Brazil [8,11,21-24].

Bone marrow transplantation should not be offered as initial therapy for patients with classic PNH due to the associated morbidity and mortality risks, but it is the definitive therapy for PNH, and the cost-effectiveness of each therapy should always be evaluated individually, according to the particularities of each case [12,19,22-25].

## 2. CASE REPORT

The patient was already being followed up in Hematology due to the condition diagnosed in childhood due to changes in the urinalysis in a routine examination, associated with pre-hypertension and mild hepatosplenomegaly. (He didn't know the exact date of the initial events. He just said it was in his childhood).

A 25 years old, male, student, in regular follow-up in the Hematology sector due to Paroxysmal Nocturnal Hemoglobinuria in regular use of Eculizumab. He reports a month ago that he suddenly noticed, upon waking up in the morning, blurring and decreased visual acuity in her left eye. He denied pain, photopsias, scotomas or ocular hyperemia. He stated that for approximately 4 months he has not used the medication regularly because it was lacking. Referred for ophthalmologic evaluation to elucidate sudden decrease in visual acuity.

He denied comorbidities and previous use of other medications, as well as the daily use of eye drops, surgeries and eye procedures.

Results of viral and VDRL serologies

Hematocrit: Macrocytosis, hypochromia. Polychromatophilia. Elongated, teardrop-shaped erythrocytes.

On eye examination, visual acuity with correction was 20/20 in the right eye (RE) and counting fingers at 1 meter in the left eye (LE).

Biomicroscopy showed afferent pupillary defect in the LE, iris atrophy at the pupillary edge 360° AO. The rest of the exam was normal.

Intraocular pressure was 13/11 mmHg at 11:50 a.m.

The retinography showed

RE regular optic disc (RE), L/R 0.5x0.5, tortuous vessels, free macula with preserved foveolar brightness, applied retina (Fig. 1).

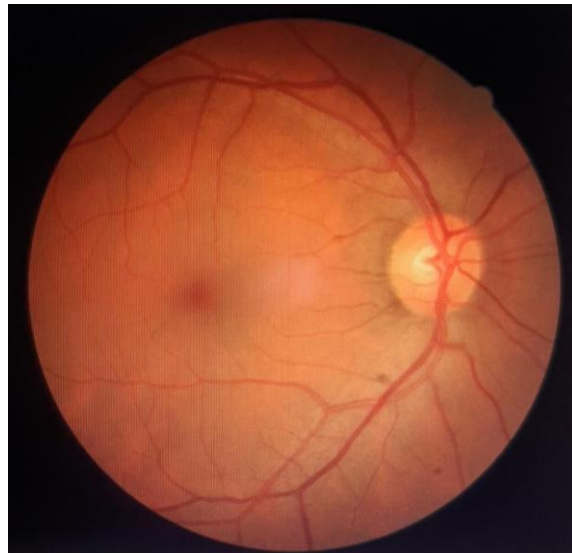
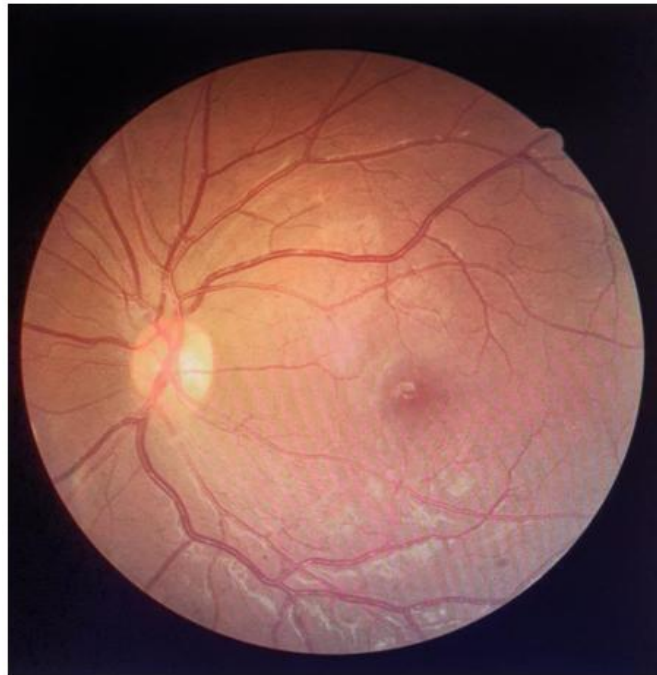

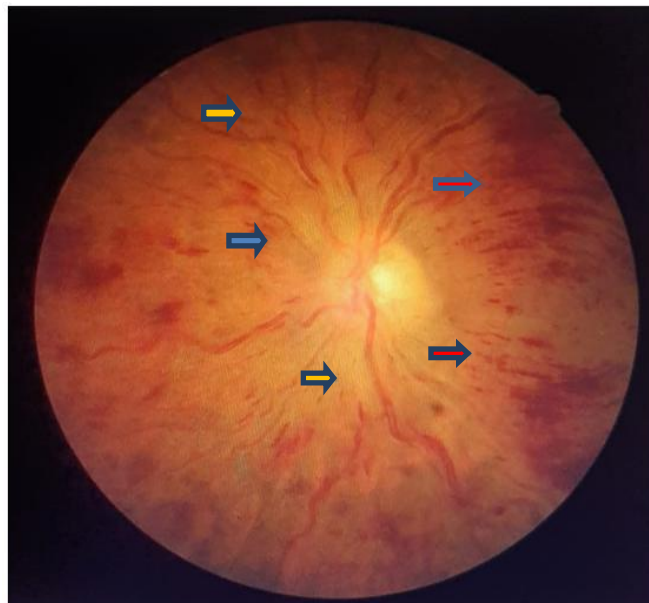
Fig. 1. Optic disc (RE)

Table 1. Laboratory tests showed

Hemoglobin 5.7	Hematocrit 16.6%	MCV 110.4
HCM 37.6	CHCM 34.1	RDW 27.8
Red cells 1.51	Platelets 74,000	D-dimer 1737
ESR 136	TAP 14.4	INR 1.11
PTT 30.9	P/T Ratio 1.00	Non-Reagent VDRL
Anti -HCV Non-Reagent	HBsAg Non-Reagent	Total Anti-HBc Non-Reagent
Anti-HBs Reagent	Anti HIV 1 and 2 Non-Reagent.	Leukometry 3,100 (Basophil 0 / Eusinophil 0 / Segmented 48 / Rods 3 / Lymphocytes 40 / Monocytes 9)



**Fig. 2. Left eye with regular optic disc, cup/disc ratio physiological, vessels without alterations, without tortuosities, macula with preserved foveolar brightness**



**Fig. 3. Post operative stage. Yellow arrow showing vascular tortuosity. Red arrow revealing candle flame hemorrhage. Blue arrow showing optic disc edema**

There is no angiography for the case illustration. Just these evidence to confirm the case.

After ophthalmologic evaluation and discussion of the case with the hematology team, the patient returned to use of Eculizumab and is being followed up in both sectors in order to control his

underlying pathology and start therapy with anti-angiogenic agents and laser photocoagulation.

### 3. DISCUSSION

Paroxysmal nocturnal hemoglobinuria (PNH) is an acquired disorder characterized by hemolysis,

thrombosis, and bone marrow failure caused by defective expression of glycosylphosphatidylinositol-anchored (GPI-anchored) complement inhibitors. Most commonly, PNH is caused by the loss of PIGA (somatic mutation in class A phosphatidylinositol glycan) function, which is necessary for GPI biosynthesis [4,7,9,17,22].

PNH is a rare disorder characterized by chronic acquired hemolytic anemia, often associated with recurrent nocturnal exacerbations, recurrent infections, neutropenia, thrombocytopenia, and episodes of venous thrombosis. Its clinical course is highly variable [8,19,20-24].

PNH often appears in association with bone marrow failure, particularly aplastic anemia and myelodysplastic syndrome. It is also an acquired thrombophilia, presenting with a variety of venous thrombosis, manifesting mainly with intra-abdominal thrombosis, here the main cause of mortality [13,19,20-24]. The triad of hemolytic anemia, pancytopenia and thrombosis characterize PNH, a condition present in the patient described above.

Therefore, in PNH, there is an increase in the susceptibility of red blood cells to complement and, consequently, to hemolysis to thrombotic events, which in the present report was evidenced by the occlusion of the central retinal vein, a rare site of thrombotic involvement secondary to PNH [13,15,19-22].

Eculizumab, a monoclonal antibody, is an effective drug therapy for PNH, being essential to control the pathology [16,17,19,22,23]. The patient, until the moment of the consultation, had not presented any previous thrombotic event, and the CVO the initial vascular episode secondary to a lack of control of the underlying pathology, see the interruption of Eculizumab due to its unavailability.

#### 4. CONCLUSION

Paroxysmal nocturnal hemoglobinuria (PNH) is a rare disorder of bone marrow failure that manifests with hemolytic anemia, thrombosis, and peripheral blood cytopenias. Thrombotic phenomena are the main cause of morbidity and mortality in PNH. The prevention of thrombosis in this disease and the effective treatment of thrombosis at the beginning of its presentation are fundamental. Eculizumab is the best drug therapy for PNH because it acts on the

pathophysiology of the disease and prevents its clinical manifestations.

Patients with hemolytic anemia, unexplained thrombosis, especially in uncommon sites, cytopenias and bone marrow failure syndromes, dysphagia, and unexplained abdominal pain should be screened for PNH. PNH patients can benefit greatly from the treatments available, with a reduction in the risk of serious sequelae and a considerable improvement in their quality of life. So that the patient continues to be followed up in the ophthalmology department, with decreased visual acuity ipsilateral to the lesion, with a relative afferent pupillary defect on that side.

#### CONSENT

All authors declare that 'written informed consent was obtained from the patient'.

#### ETHICAL APPROVAL

As per international standard or university standard written ethical approval has been collected and preserved by the author(s).

#### COMPETING INTERESTS

Authors have declared that no competing interests exist.

#### REFERENCES

1. Čermák J. Paroxysmal nocturnal hemoglobinuria. *Vnitr Lek.* Summer. 2018; 64(5):508-513.
2. Bektas M, Copley-Merriman C, Khan S, Sarda SP, Shammo JM. Paroxysmal nocturnal hemoglobinuria: Current treatments and unmet needs. *J Manag Care Spec Pharm.* 2020;26(12-b Suppl): S14-S20.
3. Nishimura JI. Paroxysmal nocturnal hemoglobinuria and thrombosis in the era of eculizumab. *Rinsho Ketsueki.* 2018; 59(8):1042-1047.
4. Fattizzo B, Kulasekararaj AG. Second-generation C5 inhibitors for paroxysmal nocturnal hemoglobinuria. *BioDrugs.* 2020; 34(2):149-158.
5. Peacock-Young B, Macrae FL, Newton DJ, Hill A, Ariëns RAS. The prothrombotic state in paroxysmal nocturnal hemoglobinuria: a multifaceted source. *Haematologica.* 2018;103(1):9-17.

6. Dulau-Florea A, Maric I, Calvo KR, Braylan RC. Detection of paroxysmal nocturnal hemoglobinuria (PNH) in bone marrow aspirates. *Semin Hematol.* 2019;56(1): 65-68.
7. Lee JW, Kulasekararaj AG. Ravulizumab for the treatment of paroxysmal nocturnal hemoglobinuria. *Expert Opin Biol Ther.* 2020;20(3):227-237.
8. Nishimura JI. Antibody therapy for paroxysmal nocturnal hemoglobinuria. *Rinsho Ketsueki.* 2020;61(8):929-936.
9. Arcavi M, Ceballo F, Caracciolo MB, Lazarowski A. Paroxysmal nocturnal hemoglobinuria: Test to monitor the action of eculizumab treatment. *Int J Lab Hematol.* 2020;42(3):335-340.
10. Kamei RW. Esclerite posterior associada à oclusão da veia central da retina e edema macular cistoide: relato de caso [Posterior scleritis associated with central retinal vein occlusion and cystoid macular edema: case report]. *Arq Bras Oftalmol.* 2012; 75(5):358-60.
11. Brunner M, Haueter I, Valmaggia C. Dexamethasonimplantat zur Behandlung des Makulaödems bei retinalen venösen Gefäßverschlüssen und entzündlichen Augenerkrankungen [Dexamethason implant in the treatment of macular edema in retinal vein occlusion and intraocular inflammatory disease]. *Klin Monbl Augenheilkd.* 2013;230(4):396-400.
12. Iijima H. Mechanisms of vision loss in eyes with macular edema associated with retinal vein occlusion. *Jpn J Ophthalmol.* 2018; 62(3):265-273.
13. Noma H, Funatsu H, Mimura T, Shimada K. Visual function and serous retinal detachment in patients with branch retinal vein occlusion and macular edema: A case series. *BMC Ophthalmol.* 2011; 11:29.
14. Zou X, Dai RP, Dong FT. Correlation between photoreceptor layer and visual acuity in eyes with persistent cystoid macular edema secondary to branch retinal vein occlusion. *Zhonghua Yan Ke Za Zhi.* 2010;46(11): 1006-10.
15. Lee SE, Lee JW. Safety of current treatments for paroxysmal nocturnal hemoglobinuria. *Expert Opin Drug Saf.* 2021;20(2):171-179.
16. Kirito K. Expansion of paroxysmal nocturnal hemoglobinuria clones in MPLW515L mutation harboring primary myelofibrosis. *Ann Hematol.* 2020;99(11): 2707-2709.
17. Chauhan AJ, Wiffen LJ, Brown TP. COVID-19: A collision of complement, coagulation and inflammatory pathways. *J Thromb Haemost.* 2020;18(9):2110-2117.
18. Rosa J, Arruda A, Rodrigues AL, Soares MR. Paroxysmal Nocturnal Hemoglobinuria: Case Report of a Rare Cause of Thrombosis in the Pediatric Age. *J Pediatr Hematol Oncol.* 2021;43(2):e240-e242.
19. Kurashige Y, Tsujikawa A, Murakami T, Miyamoto K, Ogino K, Muraoka Y, et al. Changes in visual acuity and foveal photoreceptor integrity in eyes with chronic cystoid macular edema associated with retinal vein occlusion. *Retina.* 2012;32(4): 792-8.
20. Scott IU, Oden NL, VanVeldhuisen PC, Ip MS, Blodi BA, Chan CK; SCORE2 Investigator Group. Month 24 Outcomes After Treatment Initiation With Anti-Vascular Endothelial Growth Factor Therapy for Macular Edema Due to Central Retinal or Hemiretinal Vein Occlusion: SCORE2 Report 10: A Secondary Analysis of the SCORE2 Randomized Clinical Trial. *JAMA Ophthalmol.* 2019;137(12):1389-1398.
21. Etheridge T, Dobson ETA, Wiedenmann M, Oden N, VanVeldhuisen P, Scott IU, et al. Ellipsoid zone defects in retinal vein occlusion correlates with visual acuity prognosis: SCORE2 Report 14. *Transl Vis Sci Technol.* 2021;10(3):31.
22. Braithwaite T, Nanji AA, Lindsley K, Greenberg PB. Anti-vascular endothelial growth factor for macular oedema secondary to central retinal vein occlusion. *Cochrane Database Syst Rev.* 2014;5(5): CD007325.
23. Mitry D, Bunce C, Charteris D. Anti-vascular endothelial growth factor for macular oedema secondary to branch retinal vein occlusion. *Cochrane Database Syst Rev.* 2013;(1): CD009510.
24. Tomazos I, Sierra JR, Johnston KM, Cheung A, Brodsky RA, Weitz IC. Cost

- burden of breakthrough hemolysis in patients with paroxysmal nocturnal hemoglobinuria receiving ravulizumab versus eculizumab. *Hematology*. 2020; 25(1):327-334.
25. Fattizzo B, Serpenti F, Giannotta JA, Barcellini W. Difficult Cases of Paroxysmal Nocturnal Hemoglobinuria: Diagnosis and Therapeutic Novelties. *J Clin Med*. 2021; 10(5):948.

© 2022 Miguel et al.; This is an Open Access article distributed under the terms of the Creative Commons Attribution License (<http://creativecommons.org/licenses/by/4.0>), which permits unrestricted use, distribution, and reproduction in any medium, provided the original work is properly cited.

*Peer-review history:*

*The peer review history for this paper can be accessed here:*  
<https://www.sdiarticle5.com/review-history/87209>