

# Accidental Ingestion of Laryngoscope Bulb during Emergency Endotracheal Intubation: A Case Report

Dharanindra Moturu <sup>a++\*</sup>, Balakrishna Nannapaneni <sup>a#</sup>,  
V Dinesh Kumar Gontla <sup>a†</sup>, Supriya Rayana <sup>b‡</sup>,  
Mohammad Noor Shaik <sup>c^</sup>, Devi Aruna Jyothi Bommareddy <sup>c^</sup>,  
Jahnavi Naga Pavani Pucha <sup>c^</sup> and Kali Prasad Movva <sup>d##</sup>

<sup>a</sup> Aster Ramesh Hospital, Vijayawada, Andhra Pradesh, India.

<sup>b</sup> Department of Pharmacy Practice, KL College of Pharmacy, Koneru Lakshmaiah Education Foundation, Vaddeswaram, Guntur, Andhra Pradesh, India.

<sup>c</sup> KL College of Pharmacy, Koneru Lakshmaiah Education Foundation, Vaddeswaram, Guntur, Andhra Pradesh, India.

<sup>d</sup> Royal Prince Alfred Hospital, Sydney, Australia.

## Authors' contributions

*This work was carried out in collaboration among all authors. All authors read and approved the final manuscript.*

## Article Information

### Open Peer Review History:

This journal follows the Advanced Open Peer Review policy. Identity of the Reviewers, Editor(s) and additional Reviewers, peer review comments, different versions of the manuscript, comments of the editors, etc are available here: <https://www.sdiarticle5.com/review-history/126222>

**Case Report**

**Received: 10/09/2024**

**Accepted: 12/11/2024**

**Published: 16/11/2024**

## ABSTRACT

<sup>++</sup> Consultant Critical Care Physician and in Charge Medical ICU;

<sup>#</sup> FIP Interventional Pulmonology, Consultant Pulmonologist;

<sup>†</sup> Dr NB Critical Care Medicine, Consultant Critical Care Medicine;

<sup>‡</sup> Pharm D, Assistant Professor;

<sup>^</sup> Doctor of Pharmacy Program;

<sup>##</sup> Trainee ICU;

\*Corresponding author: Email: [newgenmedico@outlook.com](mailto:newgenmedico@outlook.com);

**Cite as:** Moturu, Dharanindra, Balakrishna Nannapaneni, V Dinesh Kumar Gontla, Supriya Rayana, Mohammad Noor Shaik, Devi Aruna Jyothi Bommareddy, Jahnavi Naga Pavani Pucha, and Kali Prasad Movva. 2024. "Accidental Ingestion of Laryngoscope Bulb During Emergency Endotracheal Intubation: A Case Report". *Asian Journal of Research and Reports in Gastroenterology* 7 (1):206-9. <https://journalajrrga.com/index.php/AJRRGA/article/view/151>.

Accidental ingestion or aspiration of foreign bodies during endotracheal intubation is a rare but potentially life-threatening complication. This report highlights the accidental ingestion of a laryngoscope bulb during emergency intubation and its successful management. A 58-year-old male with multiple comorbidities, underwent endotracheal intubation for hypoxia (Spo<sub>2</sub> – 72%), tachypnea and respiratory distress. Post-intubation, an X-ray revealed a laryngoscope bulb in the stomach, which was naturally expelled via the stool. Proper equipment checks before and after intubation are crucial, and guidelines should address the management of foreign body ingestion or aspiration during intubation.

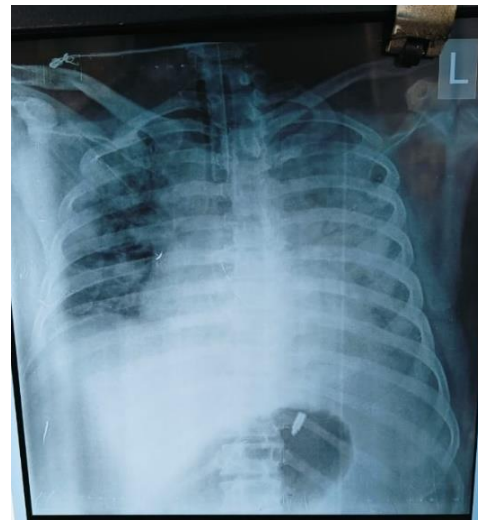
**Keywords:** Accidental ingestion; laryngoscope bulb; endotracheal intubation; foreign body; airway management.

## 1. INTRODUCTION

Endotracheal intubation is a routine procedure frequently performed in the operating room and in emergencies to maintain the airway and breathing [1]. There are numerous complications of this procedure including hypoxia, trauma to tissues, and esophageal intubation [2]. Rarely accidental aspiration or ingestion of foreign bodies like dentures and parts of equipment used for intubation occur. We present one such case of accidental ingestion of a laryngoscope light bulb.

## 2. CASE REPORT

A 58-year-old male, with a known case of hypertension, diabetes mellitus, morbid obesity, and chronic non-healing diabetic ulcer on his left leg came to the emergency department with acute onset breathlessness. After the primary survey and simultaneous resuscitation, he was found to have left lung consolidation. The airway assessment was done with the MACOCHA score which is routinely used to predict difficult intubation in critically ill. It was calculated using parameters Mallampati score III or IV (+5), Obstructive sleep apnea syndrome (+2), reduced mobility of cervical spine (+1), severe hypoxemia <80% (+1) and the score was 9. In view of hypoxia Spo<sub>2</sub> 72% and respiratory distress, endotracheal intubation with mechanical ventilation was planned, macintosh laryngoscope was used for intubation, on laryngoscopy glottic visualization was Cormack Lehane grade 3, endotracheal intubation was achieved with the help of bougie. Post-intubation air entry is bilateral and equal, connected to a mechanical ventilator in volume-controlled mode. Post-intubation x-ray showed a laryngoscope bulb in the fundic region (Fig. 1).



**Fig. 1. X-ray showing a laryngoscope bulb in the fundic region of the stomach**

The clinical abdominal examination and ultrasound were normal. A gastroenterology reference was taken, and a conservative management plan was adopted, the initiation of enteral nutrition with dietary fiber supplementation was advised. Subsequently, on day 2 abdomen chest X-ray showed no bulb in the stomach. Subsequently, the bulb was found intact in the patient's diaper. The patient's respiratory condition improved over the coming days, he was extubated and discharged to the wards.

## 3. DISCUSSION

Ingestion of a laryngoscope bulb is a rare but potentially threatening complication [2]. A few cases have been reported where a laryngoscope's bulb or other components were either aspirated or swallowed. Thapa et al. documented a case involving a lost laryngoscope bulb during endotracheal intubation in a

neurology patient [3], a case of ingestion of broken glass of a laryngoscope bulb in a patient experiencing seizures was reported by Sklar and Tandberg [4]. Saurabh Sharma et al reported a 55 years male with intracranial hematoma ingested a laryngoscope bulb following endotracheal intubation, the patient started on high fiber diet and after 4 days, the laryngoscope bulb was retrieved from the stool of the patient [5]. Muhamed S, et al reported a 68-year-old female who came to the emergency department with dyspnea, the patient had an accidental laryngoscope bulb displacement during endotracheal intubation which entered the gastrointestinal track after 3 days the bulb was found in patient stool [6]. Zeynep Ince et al reported that a full-term female newborn ingested a laryngoscope bulb during endotracheal intubation to suction meconium-stained amniotic fluid from the trachea. The infant expelled the bulb by vomiting a few hours later [2]. Naumovski et al reported a male newborn ingested a laryngoscope bulb during intubation for meconium-stained amniotic fluid, the ingested bulb was later passed naturally in the infant's feces without any complications [7] and Ozmert MA, et al reported a premature male neonate ingested a laryngoscope light bulb following endotracheal intubation. The bulb was subsequently passed naturally in the infant's feces without any complications [1]. In our case, no harm was caused to the patient. We recognized immediately that the bulb of the laryngoscope was detached accidentally and entered the gastrointestinal track. Post-intubation x-ray showed a laryngoscope bulb in the fundic region. Subsequently, the bulb was found in the diaper of the patient intact. Direct laryngoscopes tend to have more detachable small parts compared to video laryngoscopes. They need to be checked before and after intubation. The use of a video laryngoscope during difficult intubation is recommended by various guidelines [8]. Also, a review of multiple difficult airway guidelines in critically ill patients showed no information regarding the management of patients who aspirated foreign bodies into aerodigestive tracts during intubation.

#### 4. CONCLUSION

It is essential to ensure proper checking of the integrity of airway equipment both before and after endotracheal intubation. Serious and life-threatening complications can arise if the bulb is aspirated during intubation. We recommend using video laryngoscopes during difficult

intubation as suggested by various guidelines in cases of difficulty airway. This incident also highlights the importance of having a second laryngoscope available for emergency intubations. We suggest various authorities of airway management in critically ill and general anesthesia include guidelines for managing foreign bodies in the aerodigestive tract during intubation.

#### CONSENT

As per international standards or university standards, patient's written consent has been collected and preserved by the authors.

#### ETHICAL APPROVAL

It is not applicable.

#### DISCLAIMER (ARTIFICIAL INTELLIGENCE)

Author(s) hereby declare that NO generative AI technologies such as Large Language Models (ChatGPT, COPILOT, etc.) and text-to-image generators have been used during the writing or editing of this manuscript.

#### COMPETING INTERESTS

Authors have declared that no competing interests exist.

#### REFERENCES

1. Özdemir Ö, Koçyiğit A, Çiçek C, Koltuksuz U, Ergin H. An unusual complication of endotracheal intubation: ingestion of a bulb in a premature neonate. *Turkish Journal of Pediatrics*; 2016.
2. Ince Z, Tucu D, Çoban A. An unusual complication of endotracheal intubation: Ingestion of a laryngoscope bulb. *Pediatric emergency care*. 1998;14(4):275-6.
3. Thapa L, Paudel R, Basnet A, Shilpakar R, Majhi PC, Rana PV. A rolling blackout oral cavity. *Journal of College of Medical Sciences-Nepal*. 2010;6(3):44-5.
4. Sklar DP, Tandberg D. Glass ingestion from fracture of a laryngoscope bulb. *The Journal of Emergency Medicine*. 1992; 10(5):569-71.
5. Sharma S, Gupta S, Nagyan T, Nasar MA, Some S, Agarwal PN. A Case of Ingested Laryngoscope Bulb During Emergency Endotracheal Intubation. *Indonesian*

- Journal of Medical Sciences and Public Health. 2020;1(2):51-3.
6. Muhamed S, Mathew S, Rao BM, Arunkumar HD. A case of ingested laryngoscope bulb during emergency endotracheal intubation. Saudi Journal of Anaesthesia. 2017;11(2):259.
  7. Naumovski L, Schaffer K, Fleisher B. Ingestion of a laryngoscope light bulb during delivery room resuscitation. Pediatrics. 1991;87(4):581-2.
  8. Higgs A, McGrath BA, Goddard C, Rangasami J, Suntharalingam G, Gale R, Cook TM, Society DA. Guidelines for the management of tracheal intubation in critically ill adults. British Journal of Anaesthesia. 2018;120(2):323-52.

**Disclaimer/Publisher's Note:** The statements, opinions and data contained in all publications are solely those of the individual author(s) and contributor(s) and not of the publisher and/or the editor(s). This publisher and/or the editor(s) disclaim responsibility for any injury to people or property resulting from any ideas, methods, instructions or products referred to in the content.

---

© Copyright (2024): Author(s). The licensee is the journal publisher. This is an Open Access article distributed under the terms of the Creative Commons Attribution License (<http://creativecommons.org/licenses/by/4.0>), which permits unrestricted use, distribution, and reproduction in any medium, provided the original work is properly cited.

*Peer-review history:*

*The peer review history for this paper can be accessed here:*  
<https://www.sdiarticle5.com/review-history/126222>