



# **Results of Anterior Cruciate Ligament Injuries by Arthroscopic Reconstruction Using Semitendinosus Tendon**

**Nuresh Kumar Valecha<sup>1</sup>, Niaz Hussain Keerio<sup>2\*</sup>, Masood Ahmed Qureshi<sup>3</sup>,  
Syed Sajid Hussain<sup>4</sup>, Hassan Amir us Saqlain<sup>4</sup>, Ghazanfar Ali Shah<sup>5</sup>  
and Syed Shahid Noor<sup>6</sup>**

<sup>1</sup>Dibba Hospital Fujairah, United Arab Emirates.

<sup>2</sup>Muhammad Medical College and Hospital Mirpurkhas, Pakistan.

<sup>3</sup>King Abdul Aziz Hospital Makkah Saudi Arabia.

<sup>4</sup>Al Qassimi Hospital Sharjah, United Arab Emirates.

<sup>5</sup>CHK/SMBBIT, Dow University of Health Sciences, Karachi Pakistan.

<sup>6</sup>Liaquat National Hospital and medical College Karachi, Pakistan.

## **Authors' contributions**

*This work was carried out in collaboration among all authors. All authors read and approved the final manuscript.*

## **Article Information**

DOI: 10.9734/JPRI/2021/v33i28B31548

### Editor(s):

(1) Dr. Wenbin Zeng, Xiangya School of Pharmaceutical Sciences, Central South University, China.

### Reviewers:

(1) Yaodong Gu, Ningbo University, China.

(2) Arkaitz Castañeda, University of Deusto, Spain.

Complete Peer review History: <http://www.sdiarticle4.com/review-history/67727>

**Original Research Article**

**Received 01 March 2021**

**Accepted 05 May 2021**

**Published 13 May 2021**

## **ABSTRACT**

**Objectives:** This study was designed to evaluate the surgical management of anterior cruciate ligament injuries by arthroscopic reconstruction using semitendinosus grafts.

**Methodology:** This study was conducted by Dibba Hospital Fujairah, United Arab Emirates from March 2017- to March 2020. A total of 40 patients were selected for this research. In our study, we used arthroscopy assisted ACL reconstruction technique with single bundle quadrupled semitendinosus tendon autograft. This autograft was inserted from the ipsilateral limb with the help of endobutton femoral side of graft was fixed and with bioabsorbable screw tibial side of graft was stabilized. A single surgeon performed all the surgeries.

**Results:** In our observations, we reported that the majority of the patients had exposure of ACL injury in their middle adult age (32-38 years old) due to high engagement in physical activities (67.8%) like biking, playing sports and many others. The ratio of right knee injury site was comparatively high (53.5%) than the left one (46.4%).

**Conclusion:** From the results, we concluded that the younger age group is more prone to anterior Cruciate ligament injury. ACL reconstruction with Semitendinosus tendon autograft helps in maintaining knee movement and assist in early knee stability.

*Keywords: Anterior cruciate ligament; arthroscopy; semitendinosus tendon.*

## 1. INTRODUCTION

Anterior Cruciate ligaments are considered the best method to prevent the knee from anterior translation and act as a knee stabilizer [1]. It also helps to reduce valgus stress and rotational stress. The Anterior Cruciate ligament is the most prone part of the human body for injuries [1]. In recent years 0.24 to 0.34 ACL incidents were reported and labelled as the knee's most prevalent injury [2]. ACL injuries also induce cartilage damage and knee arthrosis which need proper management. Management of these injuries relies upon the intrinsic (physical strength of patient) and extrinsic risk factors (environmental factors) of ACL injuries. Intrinsic factors are also based on the Q-angle of the knee, ACL size, intercondylar notch, and tibia slope [1]. Whereas extrinsic factors involved friction of the ground, climate factor (especially dry climate enhance the torsional factors of patients if they engaged in any sports activities like a football) [2-3]. Due to the high frequency of ACL incidents, many authors were interested in studying ACL surgery outcomes in past years. Reconstruction of Anterior Cruciate ligament is considered as the most appropriate method for decreasing the ACL morbidity ratio [2]. This method has a high efficacy ratio due to optimal activation of knee joint surrounding muscles. ACL injuries directly affect the pattern of surrounding muscles, only the reconstruction method can resolve the activity of rupture muscles. The proper muscles activity can be achieved through technical factors of ACL reconstruction, including fixation method, graft choice and by practising complete rehabilitation protocol [3].

Advance arthroscopic techniques play a vital role in ACL reconstruction surgery, especially in anterior and posterior cruciate ligaments [4]. These advanced arthroscopic techniques provide better results for small incisions. This method helps in the examination of the intercondylar notch for the placing of tunnel and attachment

sites [5]. Arthroscopic assisted ACL reconstruction provides less postoperative pain and helps in regain early motion. Tendon bone autograft is a widely used arthroscopic assisted ACL reconstruction method in recent years [6]. In recent years this method gains attention after observing fewer chances of a posterior blow out and a massive improvement in femoral tunnel placement [7]. This method is best suitable for those patients who were engaged in aerobic activities [7]. Nowadays, physicians prefer ACL reconstruction with soft grafts like semitendinosus [8]. These semitendinosus grafts have superiority over the bone-patellar tendon-bone graft due to their mechanical resistance [9]. Another reason for its dominance is due to less anterior knee pain. In the past, many studies reported a high proficiency ratio of this method with more minor postoperative complications [10]. This study was designed to evaluate the surgical management of anterior cruciate ligament injuries by arthroscopic reconstruction using semitendinosus grafts. We formulate a hypothesis that females have high tendency of ACL injuries as compared to men.

## 2. METHODOLOGY

This study was conducted by Dibba Hospital Fujairah, United Arab Emirates from March 2017- to March 2020. A total of 40 patients were selected for this research. During follow up, six patients required revision in ACL reconstruction, and six patients were lost in followup after surgery, so these 12 patients were excluded from the study. The rest 28 patients were observed in a minimum of two years of s follow up. We include 18-45 years old patients who were suffering from grade 1, 2 meniscal injuries. All the patients with associated articular condylar fractures and multi ligamentous damages were excluded from this research. Patients with a knee infection, congenital diseases, and previous surgery history were also excluded from this research. Those who fulfilled inclusion criteria were further undergone through complete clinical

examination. We asked about the history of injury, were concerned with the mode of injury and trauma severity. Later on, patients were further observed by the Lachman knee scoring system.

Radiography examinations were proceeded before and after surgery. MRI of their knee evaluated all the patients. For surgery, we used the anteromedial portal technique. In our study, we used arthroscopy assisted ACL reconstruction technique with single bundle quadrupled semitendinosus tendon autograft. This autograft was inserted from the ipsilateral limb with the help of endobutton femoral side of graft was fixed and with bioabsorbable screw tibial side of graft was stabilized. A single surgeon performed all the surgeries. All the patients were hospitalized for two days after surgery and after discharge, they were not allowed to engage in any activity for six weeks. After release, patients were observed at two weeks, six weeks, three months, six months, nine months and two years of surgery to analyse the surgical outcomes. We followed pre and post-operative symptoms and assessed patients with the Lachman test after surgery.

### 3. RESULTS

In Table 1, we mentioned patient age, mode of injury, and site of injury. We observed majority of the patients had exposure in their middle adult age (32-38 years old) due to high engagement in physical activities (67.8%) like biking, playing sports and many others. The ratio of right injury site was comparatively high (53.5%) than the left one (46.4%).

In Table 2, we presented the surgical information of all patients, including duration of injury to surgery, symptoms, graft site, knee flexion and post-operative complications. In the majority of the cases, surgery was executed after six months of damage, with an 8mm graft due to severe pain and swelling. After surgery, wound infection and knee pain were highly observable.

In Table 3, we mentioned the Lachman score, and in Table 4 Lachman test score according to performance was noted. In half cases, good outcomes were observed.

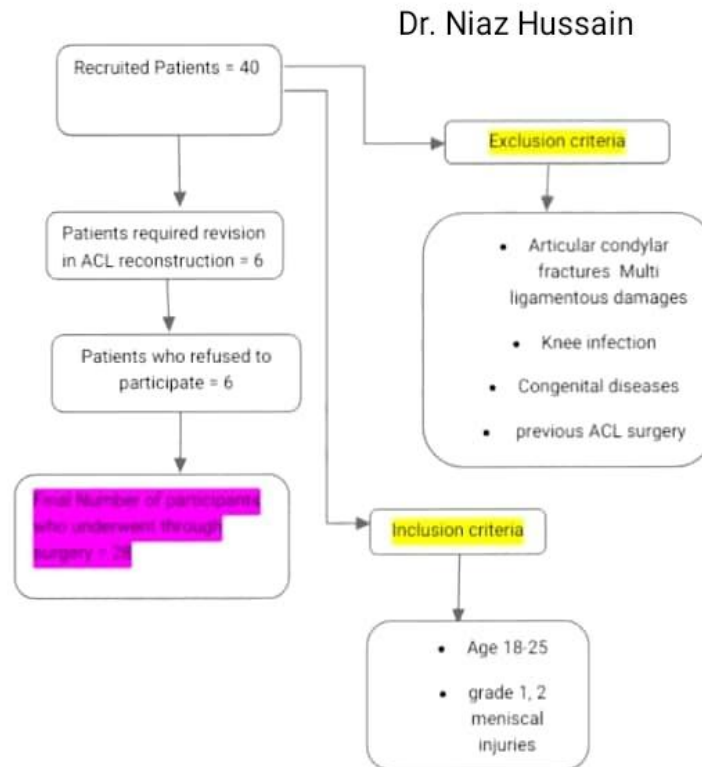


Fig. 1. Diagram representation of methodology

**Table 1. Information related to patient age, mode of injury, and site of injury**

Variables	N	Percentage
Age		
39-45 years	2	7.1%
32-38	8	28.5%
25-31	6	21.4%
18-24	12	42.8%
Mode of injury		
Sports	19	67.8%
Household injuries	2	7.1%
Fall from height	5	17.8%
RTA	2	7.1%
Injury site		
Right	15	53.5%
Left	13	46.4%

**Table 2. Preoperative symptoms, surgical procedure and postoperative outcomes of patients**

Variables	N (%)
Duration from injury to surgery	
Upto 3 weeks	0
3 weeks- 3 months	3 (10.7%)
3 months to 6 months	7 (25%)
More than 6 months	18 (64.2%)
Graft size	
> 9 mm	8 (28.5%)
8 mm	15 (53.5%)
7 mm	5 (17.8%)
Knee flexion	
0-140°	22 (78.5%)
0-130°	6 (21.4%)
0-120°	0 (0%)
Symptoms	
Pain	18 (64.2%)
Locking	4 (14.2%)
Swelling	6 (21.4%)
Postoperative complications	
Thigh muscle wasting (2-3cm)	9 (32%)
Superficial Infection	3 (10.7%)
Graft site tenderness	0 (0%)
Deep Infection	0 (0%)
Graft failure	0 (0%)
Joint effusion	1 (3.5%)
sense of giving away during exertion	3 (10.7%)
knee pain	4 (14.2%)

**Table 3. Pre and post operative lachman score**

Lachman test	lachman test grade			
	Grade III	Grade II	Grade I	Nil
Pre-Operative score	10	15	5	0
Postoperative score	0	0	10	18

**Table 4. Outcomes of lachman knee scoring performance**

Score grading	Preoperative N %	Postoperative N %
Poor (less than 65)	8 (28.5%)	0 (0%)
Fair (65-83)	20 (71.4%)	2 (7.12)
Good (84-90)	0	14 (50%)
Excellent (> 90)	0	12 (42.8%)

#### 4. DISCUSSION

The primary role of the ACL is to restore knee stability. Previous literature observed successful clinical outcomes of ACL while using with graft [9]. The ACL reconstruction choice is still evolving, but in the past, many researchers used the Endobutton and the Biocomposite interference screws and gained positive postoperative outcomes [10]. In our study, we used arthroscopy assisted ACL reconstruction technique with graft inserted from the ipsilateral limb with the help of endobutton femoral side of graft was fixed and with bioabsorbable screw tibial side of graft was stabilized. A single surgeon performed all the surgeries. On the other hand, for the tibial side, bioabsorbable interference screw was used with the aperture fixation method. We reported a  $30.53 \pm 7.24$  mean age of patients. These results are by the previous study of Siebold et al [11]., in which he revealed 29 years mean age of patients, whereas Specchiulli et al. [12]., reported 27 years mean age of their patients. Our results are relatively close to the previous study of D Chaudhary et al. [13] (26.5 mean age), N.M. Jomha et al. [14] (26 years age), D.J. Deehan et al. [15] (25 years mean age).

Recently the study of Padya et al. [16] observed a high prevalence of injury in female, but in our results, we observed that male are more prone to injury due to their increased exposure to the environment. Furthermore, Brown et al. claim that the limb's sidedness does not affect the damage and recovery period. In our study, we observed that 46.4% of patients had right side injury, and 53.5% of patients were reported with a left side injury.

In our study, the majority of the patients injured due to increased engagement in sports activities (67.8%). Patients were more engaged in jumping, running, basketball, volleyball. We observed 17.8% of cases arises due to traffic accidents. Comparing these results with D Chaudhary et al., our results are parallel by his research. In his study, he observed 66.7% of injured cases due to sports activities, 30.8% due to traffic accidents, and 2.2 % reported due to household injuries.

In many studies, researchers claim that ACL surgery has better outcomes if it proceeds after three weeks of injury. In our research, we treat patients with bracing for reducing swelling [17-19]. After the examination of symptoms, patients were sent to the surgery. In many patients, we observed that perioperative edema, ROM and hyperaemia restricted the postoperative outcomes.

A recent systematic review conducted by Conte EJ et al. [20] observed that ACL reconstruction with 8mm or larger quadrupled hamstring decreases surgery's failure. These results are also reported in a previous study of Mariscalco MW et al. [21], in which he observed failure of ACL reconstruction in 263 patients treated with <8mm graft. Another study reported that graft length size depends on the patient BMI, and its diameter depends on the thickness of the patient thigh. In our research, we used an 8mm diameter graft in 53.5% of patients; in 17.8%, we used less than 7 mm graft, and in 28.5% cases, graft size was above 9mm. After the surgery, we get 96% positive outcomes in average follow up of 25.4 months—this high ratio of positive effects observed due to the strict protocol of rehabilitation. Patients were not allowed to engage in further sports activities for six months. During this period, the Lysholm score was constantly recorded at six months, one year and two years after surgery. We observed improvement in Lysholm score after surgery. The mean Lysholm score before surgery was reported as  $66 \pm 5.2$ , and after surgery, we kept a mean  $88.70 \pm 5.54$  lysholm score of patients with significant statistical value ( $p < 0.01$ ). During the two years follow up, our study examined 42.8% of cases with excellent outcomes, 50% with good results. With an overall 95% success rate, all patients regain their preinjury activity level.

These results are parallel to the previous study of Gulick et al. [22], in which he observed 84% of patients regain their activity level. Lysholm score of our research is by the last survey of Daniel B. O'Neill et al. [23], H. E. Bourke et al. [24] and Williams et al. [25]. In their study; they observed 91-93% improvement in Lysholm score during

pre and post-operative duration. Discussing the post-operative complications, we observed wound infection in 3 cases; in nine patients, we observed severe swelling, and in 4 cases, we observed knee pain. On the other hand, we record >120 degrees ROM in all patients.

## 5. CONCLUSION

From the results, we concluded that the younger age group is more prone to anterior Cruciate ligament injury. ACL reconstruction with Semitendinosus tendon autograft helps in maintaining knee movement and assist in early knee stability. ACL injuries required proper pre and post-operative management to minimize complications. Adequate planning and radiological assessment are needed before surgical intervention.

## CONSENT

As per international standard or university standard, patients' written consent has been collected and preserved by the author(s).

## ETHICAL APPROVAL

As per international standard or university standard written ethical approval has been collected and preserved by the author(s).

## COMPETING INTERESTS

Authors have declared that no competing interests exist.

## REFERENCES

1. Cor van der Hart P, Michel PJ, Van den Bekerom, Thomas Patt W. The occurrence of osteoarthritis at a minimum of ten years after reconstruction of the anterior cruciate ligament; *Journal of Orthopaedic Surgery and Research*. 2008;3:24. 2.
2. Matjaz Sajovic. Simultaneous Bilateral Anterior Cruciate Ligament (ACL) Reconstruction with use of Hamstring Tendon Autografts: a Case Report. *Journal of Surgery*. 2013;1(1):1-5. 3.
3. Adil Ajuied, Christian Smith, Fabian Wong, Simon Hoskinson, Diane Back, Andrew Davies. A Survey of Rehabilitation egimens Following Isolated ACL Reconstruction. *JMED Research*. 2014;1-9.4.
4. Kostas Patras A, Giorgos Ziogas A, Stavros Ristanis A, Elias Tsepis AB, Nicholas Stergiou ac, Anastasios Georgoulis Da. ACL reconstructed patients with a BPTB graft present an impaired vastus lateralis neuromuscular response during high intensity running. *Journal of Science and Medicine in Sport*. 2010;13:573-577. 5.
5. Anthony M, Buoncristiani MD, Fotios P, Tjounmakaris MD, James Starman S, Mario Ferretti BS et al. Anatomic Double-Bundle Anterior Reconstruction. *Arthroscopy: Cruciate the Ligament Journal of Arthroscopic and Related Surgery*. 2006;22(9):10001006.6.
6. Terry Canale S, James Beaty H. *Arthroscopy of the Lower Extremity: Campbell's operative orthopaedics*. 2006;11th edition,2855-2856. 7.
7. Wang HD, Gao SJ, Zhang YZ. Comparison of Clinical Outcomes After Anterior Cruciate Ligament Reconstruction Using a Hybrid Graft Versus a Hamstring Autograft. *Arthroscopy*. 2018;34(5):1508-1516.
8. Yau WP, Fok AWM, Yee DKH. Tunnel Positions in Transportal Versus Transtibial Anterior Cruciate Ligament Reconstruction: A Case-Control Magnetic Resonance Imaging Study. *Arthroscopy: The Journal of Arthroscopic & Related Surgery*. 2013;29(6):1047-52. DOI:<https://doi.org/10.1016/j.arthro.2013.02.010> 9.
9. Cirstoiu C, Circota G, Panaitescu C, Niculaita R. The Advantage of Arthroscopic Anterior Cruciate Ligament Reconstruction with Autograft from the Tendons of the Semitendinosus – Gracilis Muscles for the Recovery of the Stability of the Knee. *Mædica*. 2011;6(2):109-13.
10. More ADO, Pizzolatti ALA, Fancello EA, Roesler CRdM. Ri Digiacomio Ocampo et al. Biomechanical performances of Bio Cross Pin and Endobutton for ACL reconstruction at femoral side: A porcine model. *Res. Biomed Eng [online]*. 2016;36:28-34. Available: <http://dx.doi.org/10.1590/2446-4740.0720>
11. Specchiuli F, Laforgia Mocchi, Miotta mScialpi, Solaring. Anterior cruciate ligament reconstruction: A comparison of 2 techniques. *Clin Orthop*. 1995;311:142-7.
12. Siebold R, Dehler C, Ellert T. Prospective randomized comparison of double-bundle

- versus bsingle bundle anterior cruciate ligament reconstruction. J Arth Related Surg. 2008;24:137-45.
13. Chaudhary D, Monga P, Joshi D, Easwaran R, Bhatia N, Singh AK. Arthroscopic reconstruction of the anterior cruciate ligament using bone-patellar tendonbone autograft: Experience of the first 100 cases. Journal of Orthopaedic Surgery. 2005;13 (2):147-152.
  14. Jomha NM, Pinczewski LA, Clingeleffer A, Otto DD. Arthroscopic reconstruction of the anterior cruciate ligament with patellar-tendon autograft and interference screw fixation; J Bone Joint Surg.(Br). 1999;81-B:775-9. 25.
  15. Deehan DJ, Salmon LJ, Webb VJ, Davies ALA. Pinczewski-Endoscopic reconstruction of the anterior cruciate ligament with an ipsilateral patellar tendon autograft, J Bone Joint Surg. (Br). 2000; 82-B;984-91. 26.
  16. Padya, Kolluri. Functional outcome of arthroscopic anterior cruciate ligament reconstruction using semitendinosus autograft – A prospective study. International Journal of Orthopaedics Sciences. 2017;3:353-358. DOI: 10.22271/ortho.2017.v3.i3f.61.
  17. Patond KR, Chauhan VD, Kumar N. Semitendinosus transfer for anterior cruciate ligament insufficiency. Ind J of orthopaedics. 1992;26:1.28.
  18. Shelbourne KD, Wilcken JH, Mollabashy A, DeCarlo M. Arthrofibrosis in acute anterior cruciate ligament reconstruction. The effect of timing of reconstruction and rehabilitation. Am J Sports Med. 1991;19 (4):332-6.29.
  19. Shelbourne KD, Patel DV. Timing of surgery in anterior cruciate ligament injured knees. Knee Surg Sports Traumatol Arthrosc. 1995;3(3):148-56. 30.
  20. Conte EJ, Hyatt AE, Gatt CJ, Dhawan A. Hamstring Autograft Size Can Be Predicted and Is a Potential Risk Factor for Anterior Cruciate Ligament Reconstruction Failure. Arthroscopy. 2014;3(7):882-90. DOI:http://dx.doi.org/10.1016/j.arthro.2014.03.028 31.
  21. Marscalo MW, Flanigan DC, Mitchell J, Pedroza AD, Jones MH, Andrish JT et al. The Influence of Hamstring Autograft Size on Patient Reported Outcomes and Risk of Revision After Anterior Cruciate Ligament Reconstruction: A Multicenter Orthopaedic Outcomes Network (MOON) Cohort Study. Arthroscopy: The Journal of Arthroscopic and Related Surgery. 2013;29(12):1948-53. DOI:http://dx.doi.org/10.1016/j.arthro.2013.08.025 32.
  22. Gulick TD, Yoder HN. Anterior cruciate ligament reconstruction: Clinical outcomes of patella tendon and hamstring tendon grafts. J Sports Sci Med. 2002;1:63-71
  23. Daniel B, O'Neill MD. Nassau Bay-Arthroscopic Assisted Reconstruction of the Anterior Cruciate Ligament. The Journal of Bone and Joint Surgery. 1996;78A(6):803-813.
  24. Bourke HE, Gordon DJ, Salmon LJ, Waller A, Linklater J, Pinczewski LA. The outcome at 15 years of endoscopic acl reconstruction using hamstring tendon autograft. J Bone Joint Surg Br. 2012;94-B:630-7. 36.
  25. Williams III RJ, Hyman J, Petrigalino F, Rozental T, Wickiewicz TL. Anterior ligament reconstruction with a four strand quadruple hamstring tendon autograft. J Bone Joint Surg. 2004;86:225-32.

© 2021 Valecha et al.; This is an Open Access article distributed under the terms of the Creative Commons Attribution License (<http://creativecommons.org/licenses/by/4.0>), which permits unrestricted use, distribution, and reproduction in any medium, provided the original work is properly cited.

*Peer-review history:*

*The peer review history for this paper can be accessed here:  
<http://www.sdiarticle4.com/review-history/67727>*