



Efficacy of Treatment of Diabetic Macular Edema through Frequency-Doubled ND:YAG Laser (532NM) Green Laser

**Zakaulah Gopang¹, Shabeer Ahmed Bhutto^{1*}, Safder Ali Abbasi¹,
Fayaz Ali Abbasi¹ and Vijay Nagdev¹**

¹Department of Ophthalmology, Chandka Medical College and Hospital, Shaheed Mohtarma Benazir Bhutto Medical University, Larkana, Pakistan.

Authors' contributions

This work was carried out in collaboration among all authors. Authors ZG, SAB and SAA were involved in conception of idea and study design. Authors FAA and VN did data collection and performed bench work. Author SAB performed the statistical analysis. Authors ZG and SAA managed the literature searches. All authors read and approved the final manuscript.

Article Information

DOI: 10.9734/JPRI/2021/v33i28B31545

Editor(s):

(1) Dr. Rafik Karaman, Al-Quds University, Palestine.

Reviewers:

(1) Deepak Kumawat, Oriental College of Pharmacy and Research, Oriental University, India.

(2) Xinbo Li, Casey Eye Institute, Oregon Health & Science University, USA.

Complete Peer review History: <http://www.sdiarticle4.com/review-history/68618>

Received 04 March 2021

Accepted 10 May 2021

Published 12 May 2021

Original Research Article

ABSTRACT

Objective: To determine the efficacy of Frequency-doubled Nd: YAG laser (532 nm) green laser in treatment of diabetic macular edema

Study Design: This is a descriptive case series study.

Setting: Study carried out at Ophthalmology Department, Shaheed Mohtarma Benazir Bhutto Medical University Larkana, from 01-10-2019 to 31-03-2020 (06 months).

Materials and Methods: The patients with diabetic macular edema and were advised focal laser photocoagulation with help of frequency doubled Nd: YAG laser (532 nm) green laser. Improvement in visual acuity >2 lines after 3 months on snellen's chart from the baseline was labeled as efficacy positive.

*Corresponding author: E-mail: shabeerahmadbhutto@gmail.com;

Results: The total of 150 patients were included to assess efficacy of frequency doubled Nd: YAG laser (532 nm) green laser in treating diabetic macular edema as a result improvement in visual acuity of 98 (65.33%) and no improvement or same vision in 52 (34.67%) patients was observed.

Conclusion: It is to be concluded that frequency doubled Nd: YAG laser (532 nm) green laser is an effective, useful and non-invasive diagnostic tool in treating diabetic macular edema.

Keywords: Diabetic macular edema; frequency-doubled Nd: YAG laser; diabetic retinopathy.

1. INTRODUCTION

It has been observed that the most common cause of blindness in the diabetic population is Diabetic macular edema (DME), which is a multifactorial condition [1]. Ultimately it is the disruption of the blood-retinal barrier which results in DME causing blurring in the middle or to the side of the central visual field, which if left untreated can lead to visual loss [1]. According to Early Treatment Diabetic Retinopathy Study (ETDRS), the clinical significance of macular edema is based on any one of the lesions as, 1) thickening of retina at or within 500 microns from the macular center. 2) adjacent retinal thickening due to hard exudates at or within 500 microns from the center of the macula. 3) At least 1 disk size one or more than one areas of retinal thickening having a part of which within 1 disk diameter of macular center [1,2]. DME has a strong impact on the severity of diabetic retinopathy the patient is having and also has a close association with the duration and type of diabetes [3]. Wisconsin Epidemiologic Study of Diabetic Retinopathy (WESDR) has reported the 25-year highest annualized incidences of DME [4]. DME develops within 9 years of onset of type 1 diabetes in 27% of patients according to The Diabetes Control and Complications Trial (DCCT) [5,6]. Laser photocoagulation (LP) is considered as favorable treatment for micro aneurysms focal leakage while the grid LP is useful in diffuse capillary leakage as reported by Early Treatment Diabetic Retinopathy Study (ETDRS) [7]. Another study outlined the efficacy of frequency doubled Nd:YAG (Green laser 532nm) in treating diabetic macular edema as 53.84% [8]. The maximum affinity for hemoglobin and melanin, least absorption of xanthophylls, features like less scattering and greater operating life time makes the frequency doubled green laser 532 nm a superior choice for retinal photocoagulation [9]. Frequency doubled ND: YAG laser has also been used in the treatment of a various other retinal disorders such as retinal tears, occluded retinal vein, diabetic retinopathy, Eales' disease and senile macular degeneration [10].

2. MATERIALS AND METHODS

A descriptive study with probability consecutive sampling carried out at Retina Clinic, Ophthalmology department, Shaheed Mohtarma Benazir Bhutto Medical University Larkana from 01-10-2019 to 31-03-2020. All the patients included in this study were those having macular edema. Complete ocular examination was performed that includes visual acuity both distance and near with and without glasses, colour vision, pupillary reaction, slit lamp examination and applanation tonometry for intraocular pressure. The patient's pupil was fully dilated with tropicamide 1% and phenylephrine 10% eye drops for indirect ophthalmoscopy to check fundus by 20 D and 90 D lens on slit lamp biomicroscope. Focal laser photocoagulation was performed in patients with fully dilated pupil under topical anesthesia with proparacain 5 mg drops. The following parameters setting for laser photocoagulation was observed such as, the spot size (50-100 μ m) laser power (50-100 mW), pulse duration (0.05-0.1 second) and then by using pan fundoscopic lens to focus the laser on the fundus. Patients were followed after 1, 2 and 3 months and final outcome i.e. efficacy was assessed after three 3 months. The data was analyzed on statistical software SPSS Version 22.

3. RESULTS

In this study 150 patients were included to assess efficacy of frequency-doubled Nd:YAG laser (532 nm) green laser in treatment of diabetic macular edema. Out of 150 patients 93 (62%) were male and 57 (38%) were female with mean \pm SD of age was 52.48 \pm 8.29 years. Mostly patients suffered between 10 to 17 years duration in 68(45.33%) cases with mean duration of diabetes was 20.19 \pm 7.42 years. Mean duration of macular edema was 12.48 \pm 5.26 years. Means preoperative and postoperative visual acuity were 0.543 \pm 0.228 and 0.551 \pm 0.227 respectively (Table 1). We found positive efficacy of doubled Nd: YAG Laser (532 nm) green laser was 98(65.33%) patients as shown in Fig. 1.

Efficacy of doubled Nd:YAG Laser (532 nm) green laser with respect to age group, duration of diabetes mellitus and macular edema, number of sittings and preoperative visual acuity highly significant association was found i.e. $P \leq 0.05$; but in stratification of gender and hypertension non-significant association was found i.e. $P > 0.05$ as shown from (Table 2).

4. DISCUSSION

Multiple treatment choices in case of development of diabetic complications leading to serious visual impairment followed by DME such as anti-VEGF, intravitreal steroid injections and few others along with maintaining a good glycemic index, regular checks on HbA1c levels and proper follow ups are there, But the

treatment of choice remains laser photocoagulation (PD) once the retinopathy has developed to the extent of serious vision impairment or proliferative diabetic retinopathy which reduces the ME by half the percentage patient has and hence the risk of loss of vision [11]. The minimal absorption in xanthophylls and maximum by melanin in epithelium of retina due to its beneficial characteristic wave length in comparison to blue wave length makes argon green laser (532 nm) a better, effective and safe choice for early treatment of diabetic retinopathy (ETDR) [12].

The results of this study on effectiveness of doubled Nd:YAG laser (532 nm) green laser are also comparable to the one reported by Bandello F et al and Muqit M.M et al [13,14].

Table 1. Descriptive statistics

Variable	Mean	±SD	95% Confidence Level
Age (Years)	52.48	8.29	51.14--53.81
Duration of Diabetes (Years)	20.19	7.42	18.99--21.38
Duration of macular edema(Years)	12.48	5.26	11.36--13.32
Number of Sittings	2.86	1.39	2.63--3.08
Preoperative Visual Acuity	0.543	0.228	0.50--0.57
Postoperative Visual Acuity	0.551	.0227	0.51--0.58

Table 2. Efficacy of doubled ND: YAG laser (532 NM) green laser according different variable n= 150

Variable	Efficacy		P-Value
	Yes	No	
Age Group (Years)			
• 40 to 50	35	7	0.004
• 56 to70	63	45	
Gender			
• Male	70	3	0.072
• Female	35	22	
Duration of diabetes (years)			
• 11 to 17	60	8	0.001
• 18 to 25	38	44	
Durationof macular edema (years)			
• 5 to 10	40	6	0.001
• 11 to 15	58	46	
Number Of Sittings			
• 1 to 2	72	12	0.001
• >2	26	40	
Hypertension			
• POSITIVE	25	15	0.660
• NEGATIVE	73	37	
Preoperative Visual Acuity			
• 0.1 to 0.3	40	35	0.002
• 0.4 to 0.6	58	17	

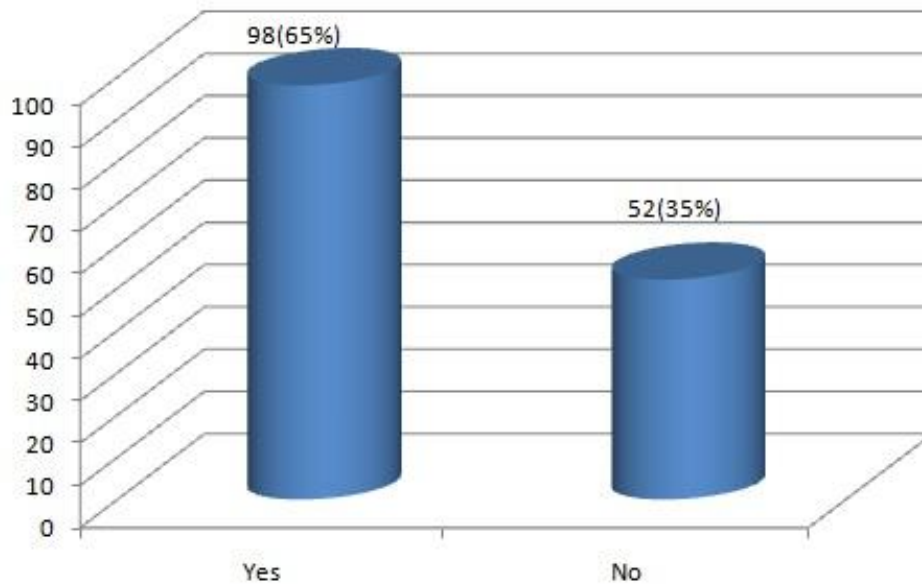


Fig. 1. Frequency of efficacy doubled ND: YAG laser (532 NM) green laser n= 150

According to some studies >90% decrement/complete remedy of ME and visual acuity improvement (complete or limited) by 80 - 95% was elicited in almost 95% of treated retinas through frequency-doubled Nd:YAG laser [15]. Equivalent effective results were obtained when treated using argon laser and frequency doubled Nd:YAG laser. In this study, the age group of 56-70 years (72%), 40-55 years (28%) and male gender manifested the highest rate of macular edema with male:female ratio as 1.6:1 which is comparable to the data reported by Kozak I et al and The Muqit M.M et al, Bandello F et al, Seiberth V et al [16,17,18,19]. In current study significant difference was found between age group, duration of diabetes mellitus and macular edema, number of sittings and preoperative visual acuity in efficacy of doubled Nd:YAG laser (532 nm) green laser i.e. $P \leq 0.05$. Similar results were also obtained by Chappelow A.V, et al [20,21].

The Strengthening pillars of this study which maximally reduced the bias are consecutive sample selection system, strict inclusion and exclusion criteria, the usage of objective definitions for outcome and even predictors. Limitations of the study includes frail study design restricting the scrutiny of firmness of evidence, limited utilization of predictor and outcome variables, probability sampling and selected number of patients with short periods of follow ups leading to slender outcomes.

Furthermore the generalization of the study is limited by data inclusive of only hospital-based patients from one unit of ophthalmology taking no consideration of disease frequency and severity at large.

5. CONCLUSION

To conclude we must say that the frequency doubled Nd:YAG laser therapy is a non-invasive, effective, fruitful diagnostic and therapeutic tool in the treatment of diabetic macular edema with convenience of solid-state laser along with favorable wavelength.

CONSENT

As per international standard or university standard, patients' written consent has been collected and preserved by the author(s).

ETHICAL APPROVAL

As per international standard or university standard written ethical approval has been collected and preserved by the author(s).

COMPETING INTERESTS

Authors have declared that no competing interests exist.

REFERENCES

1. Romero-Aroca P. Targeting the pathophysiology of diabetic macular edema. *Diabetes Care*. 2010;33(11):2484–2485.
2. Ciulla TA, Amador AG, Zinman B. Diabetic retinopathy and diabetic macular edema: pathophysiology, screening, and novel therapies. *Diabetes Care*. 2003;26(9):2653–64.
3. Shah CA. Diabetic retinopathy: A comprehensive review. *Indian J Med Sci*. 2008;62(12):500–19.
4. Klein R, Knudtson MD, Lee KE, Gangnon R, Klein BE. The wisconsin epidemiologic study of diabetic retinopathy XXIII: The twenty-five-year incidence of macular edema in persons with type 1 diabetes. *Ophthalmology*. 2009;116(3):497–503.
5. White NH, Sun W, Cleary PA, Tamborlane WV, Danis RP, Hainsworth DP, et al. Effect of prior intensive therapy in type 1 diabetes on 10-year progression of retinopathy in the DCCT/EDIC: Comparison of adults and adolescents. *Diabetes*. 2010;59(5):1244–53.
6. Saeed M, Parmar D, McHugh D. Frequency-doubled Nd:YAG laser for the treatment of exudative diabetic maculopathy. *Eye (Lond)*. 2001;15(Pt 6):712–8.
7. Sharma A, Samal A, Narang S, Gutpa A, Ram J, Gupta A. Frequency doubled Nd:YAG (532 nm) laser photocoagulation in corneal vascularisation: Efficacy and time sequenced changes. *Indian J Ophthalmol*. 2001;49(4):235–40.
8. Buckan K, Ivaniievic M, Znaor L, Bojic L, Karaman K, Galetovic D. The role of frequency-Doubled Nd: Yag Laser (532 nm) in the treatment of diabetic macular edema. *ActaClin Croat*. 2007;46(Suppl 1):13–15.
9. Gupta V, Gupta A, Kaur R, Narang S, Dogra MR. Efficacy of various laser wavelengths in the treatment of clinically significant macular edema in diabetics. *Ophthalmic Surg Lasers*. 2001;32(5):397–405.
10. Rema M, Pradeepa R. Diabetic retinopathy: An Indian perspective. *Indian J Med Res*. 2007;125(3):297–310.
11. Modi D, Chiranand P, Akduman L. Efficacy of patterned scan laser in the treatment of macular edema and retinal neovascularization. *Clin Ophthalmol*. 2009;3:465–470.
12. Seiberth V, Schatanek S, Alexandridis E. Panretinal photocoagulation in diabetic retinopathy: argon versus dye laser coagulation. *Graefes Arch Clin Exp Ophthalmol*. 1993;231(6):318–322.
13. Bandello F, Brancato R, Trabucchi G, Lattanzio R, Malegori A. Diode versus argon-green laser panretinal photocoagulation in proliferative diabetic retinopathy: a randomized study in 44 eyes with a long follow-up time. *Graefes Arch Clin Exp Ophthalmol*. 1993;231(9):491–4.
14. Muqit MM, Marcellino GR, Henson DB, Young LB, Patton N, Charles SJ. Single-session vs multiple-session pattern scanning laser panretinal photocoagulation in proliferative diabetic retinopathy: Manchester Pascal Study. *Arch Ophthalmol*. 2010;128(5):525–533.
15. Luttrull JK, Spink CJ, Musch DA. Sub threshold diode micro pulse panretinal photocoagulation for proliferative diabetic retinopathy. *Eye*. 2008;22(5):60.
16. Kozak I, Chhablani J, Mathai A, Rani P, Alshahrani S, Gupta V, et al. Comparison of the visible effect on the fundus in peripheral laser photocoagulation between conventional pattern laser and Navilas, presented at the 13th EURETINA Congress, Hamburg, Germany. 2013;26–29.
17. Muqit MM, Marcellino GR, Henson DB, Young LB, Patton N, Charles SJ. Optos-guided pattern scan laser (Pascal)-targeted retinal photocoagulation in proliferative diabetic retinopathy. *Acta Ophthalmol*. 2013;91(3):251–258.
18. Bandello F, Brancato R, Menchini U, Virgili G, Lanzetta P, Ferrari E. Light panretinal photocoagulation (LPRP) versus classic panretinal photocoagulation (CPRP) in proliferative diabetic retinopathy. *Semin Ophthalmol*. 2001;16(1):12–6.
19. Seiberth V, Schatanek S, Alexandridis E. Panretinal photocoagulation in diabetic retinopathy: Argon versus dye laser coagulation. *Graefes Arch Clin Exp Ophthalmol*. 1993;231(6):318–322.
20. Bandello F, Brancato R, Lattanzio R, Trabucchi G, Azzolini C, Malegori A. Double-frequency Nd:YAG laser vs. argon-green laser in the treatment of proliferative diabetic retinopathy: randomized study with long-term follow-up. *Lasers Surg Med*. 1996;19(2):173–176.

21. Chappelw AV, Tan K, Waheed NK, Kaiser PK. Panretinal photocoagulation for proliferative diabetic retinopathy: pattern scan laser versus argon laser. Am J Ophthalmol. 2012;153(1): 137–142.

© 2021 Gopang et al.; This is an Open Access article distributed under the terms of the Creative Commons Attribution License (<http://creativecommons.org/licenses/by/4.0>), which permits unrestricted use, distribution, and reproduction in any medium, provided the original work is properly cited.

Peer-review history:
The peer review history for this paper can be accessed here:
<http://www.sdiarticle4.com/review-history/68618>