

# The Brain Cholinergic System in Neurodegenerative Diseases

Giancarlo Pepeu<sup>1\*</sup>, Cristina Grossi<sup>1</sup> and Fiorella Casamenti<sup>1</sup>

<sup>1</sup>Department of Neuroscience, Division of Pharmacology and Toxicology, Psychology, Drug Research and Child Health, University of Florence, Viale Pieraccini 6, 50139 Florence, Italy.

## Authors' contributions

This work was carried out in collaboration between all authors. Author GP proposed the review, wrote a draft and revised the final manuscript. Author CG revised and formatted the manuscript and the references. Author FC revised the manuscript. All authors read and approved the final manuscript.

## Article Information

DOI: 10.9734/ARRB/2015/14623

### Editor(s):

(1) Prof. George Perry, University of Texas at San Antonio, USA.

### Reviewers:

(1) Arturo Solís Herrera, Human Photosynthesis Study Center, México.

(2) Anonymous, México.

(3) Anonymous, Spain.

Complete Peer review History: <http://www.sciencedomain.org/review-history.php?iid=796&id=32&aid=7169>

Review Article

Received 9<sup>th</sup> October 2014  
Accepted 10<sup>th</sup> November 2014  
Published 9<sup>th</sup> December 2014

## ABSTRACT

The neurodegenerative diseases are characterized by a progressive process of neuronal and myelin breakdown resulting in changes in the morphology and function of neurons and their death. The damage and death of the neurons is associated with an inflammatory response which involves an extensive glia activation and, through the release of inflammatory products, contributes to the neurodegenerative process. The neurodegeneration may spread throughout the brain or affect prevalently specific types of neurons such as the cholinergic neurons. Aims of this review are: 1) to describe which cholinergic nuclei degenerate in different neurodegenerative diseases, namely Alzheimer's disease, Parkinson's disease, Lewy Bodies dementia, atypical Parkinsonian diseases and alcoholic dementia; 2) to discuss the mechanisms responsible for the degeneration of the cholinergic neurons; 3) to summarize the functional consequences of the cholinergic denervation. A feature of Alzheimer's disease is the loss of the forebrain cholinergic neurons leading to a cortical cholinergic denervation. A similar loss is found in Alzheimer's disease with Lewy bodies, Parkinson disease with dementia, together with the degeneration of dopaminergic neurons, in Lewy bodies dementia and alcoholic dementia. In Lewy bodies dementia and in multiple system atrophy a loss of cholinergic neurons has been also detected in the pedunculo-pontine and laterodorsal tegmental nuclei, which are spared in Alzheimer's disease and results in a cholinergic denervation of the

\*Corresponding author: E-mail: [giancarlo.pepeu@unifi.it](mailto:giancarlo.pepeu@unifi.it);

thalamus. The degeneration of the forebrain cholinergic neurons expressing NGF receptors is attributed to a dysfunction of NGF metabolism leading to a loss of its trophic action on which those neurons depend. Whereas the direct and indirect role of  $\beta$  amyloid in NGF metabolism disruption has been clearly envisaged, the mechanisms through which tau fibrils, synuclein and ethanol exert their toxic effects on the cholinergic neurons are multiple and still matter of investigations. Finally, much evidence indicate that the loss of forebrain cholinergic neurons is largely responsible for the cognitive deficits of dementias.

*Keywords: Acetylcholine; alcoholic dementia; alzheimer's disease; lewy bodies dementia; nerve growth factor; parkinson's disease; parkinsonian diseases.*

## ABBREVIATIONS

*ACh: acetylcholine; AChE: acetylcholinesterase; AD: Alzheimer's disease; APP: amyloid precursor protein; A $\beta$ :  $\beta$ -amyloid; ChAT: acetyltransferase; DOPA: L-3,4-dihydroxyphenylalanine; LB: Lewy bodies; LBD: Lewy body dementia; MCI: mild cognitive impairment; MMP9: matrix metalloproteinase 9; MPTP: 1-methyl-4-phenyl-1,2,3,6-tetrahydropyridine; NB: nucleus basalis of Meynert; NFTs: neurofibrillary tangles; NGF: nerve growth factor; PD: Parkinson's disease; PDD: Parkinson's disease with dementia; PET: positron emission tomography; PMT: pontomesencephalo-tegmental; PPN: pedunculopontine nucleus; PSP: progressive supranuclear palsy; TrkA: tyrosine kinase A receptor; VAcT: vesicular ACh transport; WE: Wernicke's encephalopathy.*

## 1. INTRODUCTION

Neurodegeneration plays an important role in the pathogenesis of several brain diseases which for this reason are called neurodegenerative. The most common neurodegenerative diseases are Alzheimer's disease (AD), Parkinson's disease (PD), Huntington's disease, amyotrophic lateral sclerosis, but also alcohol abuse may lead to neurodegeneration.

The term neurodegeneration refers to a progressive process of neuronal, myelin or tissue breakdown resulting in changes in the morphology and function of neurons, usually resulting in their death. The damage and death of the neurons are associated with an inflammatory response [1] which involves an extensive glia activation and in turn contributes to the neurodegenerative process through the release of inflammatory products [2,3]. Neurodegeneration followed by neuronal death can be induced in experimental animals in discrete brain regions by the injection of neurotoxins [4] and by causing a neuroinflammatory response by means of intracerebroventricular infusions of bacterial lipopolysaccharides [5]. Among the neurotoxins, ethylcholine mustard aziridinium, (AF64A), an analog of choline which inhibits irreversibly high affinity choline uptake, shows some selectivity for the cholinergic neurons [6]. A selective degeneration of the forebrain cholinergic neurons

can be obtained by local injection of the immunotoxin 192 IgF saporin [7,8]. The immunotoxin acts by coupling the ribosome inactivating toxin saporin to an antibody that recognizes low-affinity nerve growth factor (NGF) receptors, which are found specifically in cholinergic neurons of the basal forebrain. Lactacystin, a proteasome inhibitor, injected in the pars compacta of the substantia nigra, has been used to destroy the cholinergic neurons of the pedunculo-pontine nucleus [9] mimicking the cholinergic lesion detected in PD [10].

The neurodegeneration may be widespread throughout the brain involving neurons and glial cells in many areas. However, some neurodegenerative diseases are characterized by the prevalent, but not necessarily exclusive, degeneration of a specific type of neuron. Examples are the degeneration of the forebrain cholinergic neurons in AD [11] and of the dopaminergic neurons in the substantia nigra in PD [12].

Aims of this review are: 1) to describe which cholinergic neurons degenerate in neurodegenerative diseases, namely AD, PD, Parkinsonian diseases and alcoholic dementia, leading to a cholinergic denervation in some brain areas; 2) to discuss the mechanisms responsible for the degeneration of the cholinergic neurons; 3) to summarize the functional consequences of the cholinergic denervation. The changes in the nicotinic and

muscarinic receptors associated with the cholinergic denervation will only be mentioned.

To some extent the present review is an update of the paper by Schlieb and Arendt [13].

## 2. THE BRAIN CHOLINERGIC SYSTEM

As result of investigations begun more than 25 years ago with the use of monoclonal antibodies to choline acetyltransferase (ChAT), the enzyme responsible for acetylcholine (ACh) synthesis from its immediate precursors, choline and acetyl-coA [14] and the works of Fibiger [15], Mesulam et al. [16], Levey et al. [17], Mufson et al. [18] and others, the following schematic description of the anatomical organization of the brain cholinergic system can be presented:

- (1) Forebrain cholinergic neurons, forming a series of nuclei in the medial septum, the diagonal band of Broca and the basal magnocellular nucleus of Meynert. Their morphologies have been recently investigated in the mouse by genetically directed sparse labeling and they appear to be among the largest and most complex neurons described to date with an axon length up to 50 cm and more than 1000 branch points [19]. Since there is no precise correspondence of the cholinergic nuclei with anatomical structures, they are usually identified, according to the recently confirmed [20] classification proposed by Mesulam et al. [16], in Ch1, located in the medial septum, Ch2 in the ascending limb of the Broca's band, Ch3 in the horizontal part of the band of Broca and Ch4 in the nucleus basalis of Meynert (NB). The cholinergic neurons represent from 50 to 75% of the cells present in these nuclei and their projections form the main cholinergic afference to the cerebral cortex, hippocampus, olfactory bulb and amygdala. The cholinergic circuitry of the human nucleus basalis has been recently reviewed by Mesulam [20] who confirms that Ch4 provides the principal source of ACh for the cerebral cortex and amygdala.
- (2) The cholinergic interneurons of the caudate nucleus and putamen.
- (3) The cholinergic nuclei of the brain stem including Ch5 in the tegmental pontine nucleus, Ch6 in the dorsolateral tegmental nucleus, Ch7 in the medial habenular nucleus and Ch 8 in the parabrachial nucleus. Ch5 and Ch6 project to the

thalamus, hypothalamus, pallidus and to the forebrain cholinergic nuclei, Ch7 projects to the interpeduncular nucleus and Ch 8 to the superior colliculus.

- (4) The motor neurons of the spinal cord.

## 3. DISEASES IN WHICH THERE IS A DEGENERATION OF THE CHOLINERGIC NEURONS

### 3.1 Alzheimer's Disease

AD is the first neurodegenerative disease in which an extensive degeneration of the cholinergic neurons was observed. Davies and Maloney [21] reported that in post-mortem brains from AD patients there was a marked reduction in ChAT. The finding was repeatedly confirmed [22-25]. The decrease in ChAT activity in the cerebral cortex and hippocampus in AD is caused by the degeneration of cholinergic nerve endings originating from neurons located in the basal forebrain and septum. A 75% loss of the cholinergic neurons in the forebrain nuclei was demonstrated by Whitehouse et al. [11] and Nagai et al. [26] in AD patients. The degeneration of the cortical cholinergic nerve endings is confirmed by the decrease in the vesicular acetylcholine transporter (VACHT) [27] and the loss of M2 muscarinic receptors in post-mortem samples taken from AD patients [28]. In the brain, M2 receptors are mostly located presynaptically and regulate ACh release [29]. The cortical cholinergic denervation in AD was confirmed by *in vivo* mapping using computed tomography and [<sup>123</sup>I] iodobenzovesamicol as a marker of VACHT [30]. Moreover, a highly significant linear relationship was found in autopsy samples between cortical gray matter volume and the NB cell number in controls and AD patients [31].

### Mechanisms responsible of the cholinergic neuron degeneration in AD

The amyloid cascade hypothesis [32,33] considers the deposition of the peptide  $\beta$ -amyloid ( $A\beta$ ) the main pathogenetic event of AD. Much evidence demonstrate the toxicity of  $A\beta$  for the cholinergic neurons, as reported in the review by Pakaski and Kalman [34]. In our laboratory, we demonstrated that preaggregated  $A\beta$  injections in the NB of adult rats is followed by a decrease in the number of cholinergic neurons, identified by ChAT immunostaining and an extensive glial reaction [35]. Moreover, the number of ChAT-

immunopositive neurons is significantly reduced in the forebrain of transgenic mice showing extensive cerebral A $\beta$  deposition and glial activation [36].

However, according to Geula et al. [37] the nucleus basalis is not a site of particularly prominent amyloid deposition and there is no correlation between plaque density and severity of cholinergic axonal loss in cortical areas. The cholinergic loss in AD is more closely related to the presence of neurofibrillary tangles (NFTs) in the forebrain cholinergic neurons than to A $\beta$  plaque deposition. According to Mesulam et al. [38] the nucleus basalis-Ch4 complex stands out as one of the most vulnerable structures to neurofibrillary degeneration. Vana et al. [39] reported that, in post mortem AD brains, the increase in the number of neurons showing initial tau pathology is accompanied by a decrease in the number of cholinergic neurons and correlates with the cognitive deficit. On the basis of these and other evidence, Giacobini and Gold [40] consider tau protein as the principal actor in AD pathogenesis.

Two questions arise: 1) are all brain cholinergic neurons equally affected in AD? 2) for which reason are the cholinergic neurons more vulnerable than other types of neurons to the pathogenetic processes causing AD? Attempting to answer to the first question, it may be mentioned that Woolf et al. [41] found in post-mortem brains of AD patients that the neurons of the pontomesencephalo-tegmental (PMT) cholinergic nuclei, Ch5–Ch8, [16,18] do not degenerate in AD contrary to the forebrain cholinergic neurons. Moreover, the cholinergic neurons in the putamen are not affected in AD [26,42] whereas a loss of ChAT activity and a decrease in the number of ChAT-positive neurons have been observed in the caudate nucleus of AD patients [22,43]. There are no reports describing degeneration and loss of the ChAT-positive spinal motor neurons in AD. However, some decrease in ChAT activity, with unaltered acetylcholinesterase (AChE) activity, has been described in the anterior and posterior grey matter of the lumbar spinal cord [44]. The decrease could be related to the reduction in the number of functioning motor units found in the thenar and soleus muscles in AD patients [45].

The reasons of these remarkable regional differences in the degeneration and loss of cholinergic neurons in AD are not yet fully understood. Woolf et al. [41] observed that the

number of plaques and tangles, the histopathological landmarks of AD, is smaller in the brain stem than in the cerebral cortex and amygdala of subjects affected by AD indicating that the brain stem is less affected by the disease. More important is the observation that the basal forebrain cholinergic neurons bind NGF whereas the PMT cholinergic neurons do not, although phenotypically similar [46]. According to Kordower et al. [47] there is an extensive NGF binding to ChAT-positive cells of the Ch1–Ch4 regions whereas the binding density in the putamen is much lower. Woolf et al. [41] found that approximately 92% of all cholinergic neurons in the basal forebrain possess receptors for NGF but NGF receptors are not in association with ChAT-positive somata in the pedunculopontine and laterodorsal tegmental nuclei. Piore and Cuello [48] reported that the degree of overlap between NGF receptors and ChAT-containing regions in the brainstem is not as great as in the forebrain.

NGF binds to two different cell surface receptors—the tyrosine kinase receptors (TrkA) and the shared p75(NTR) receptor [49] with high and low affinity, respectively. The expression of TrkA mRNA was found to be restricted to neurons of the basal forebrain, caudate-putamen with features of cholinergic cells and to magnocellular neurons of several brainstem nuclei [50]. The difference in NGF receptor expression underlies the different dependence of the cholinergic neurons on NGF. Indeed, much evidence demonstrates that the forebrain cholinergic neurons are continuously dependent on NGF for the preservation of their phenotype and function [51]. The basal forebrain cholinergic neurons are greatly reduced in adult mice in which phenotypic knockout of NGF was achieved by expressing transgenic anti-NGF antibodies [52]. In these mice, the spinal cord cholinergic neurons were not examined but since their motility was not impaired, we may assume that the motor neurons are much less NGF dependent. The trophic importance of NGF for the cholinergic forebrain neurons is also demonstrated by the observation that intracerebroventricular administration of NGF ameliorates their age-associated atrophy in old rats [53]. Moreover, NGF infusions prevent the degeneration of the ChAT-positive neurons in the NB induced by local excitotoxin injection in aging rats [54]. Since the constant presence of NGF is necessary for the survival of the forebrain cholinergic neurons, the question arises whether in AD their degeneration depends on a reduced

NGF availability. According to Mufson et al. [55], brain NGF levels remain stable throughout the course of AD and appear to be sufficient to support the cholinergic plasticity changes occurring during the initial phases of the disease. On the basis of post-mortem studies in humans and of animal experiments, Cuello et al. [56] and Iulita and Cuello [57] propose that in AD a NGF deficit results from a dysregulation of the NGF maturation cascade caused by an impaired conversion of proNGF to mature NGF and an acceleration of mature NGF degradation. According to Bruno et al. [58], the dysregulation detected in postmortem brains of AD patients can be reproduced in naïve rats by the intracerebral injection of A $\beta$  oligomers causing microglial activation and the ensuing release of inflammatory factors. Therefore, according to the pathogenetic mechanism proposed by Cuello et al. [56], the degeneration of the forebrain cholinergic neurons in AD begins with the canonical excess in A $\beta$  formation and deposition associated with an extensive neuroinflammatory response which leads to NGF metabolism dysregulation. This hypothesis finds a confirmation [57] in subjects with Down syndrome in whose brains A $\beta$  peptides progressively deposit from early life. By middle age almost all Down syndrome sufferers show the neuropathological hallmarks of AD including amyloid plaques and neurofibrillary tangles. A significant increase in proNGF levels was found in the human down brains and in the brains of the Ts65Dn mice, a murine model of Down syndrome. Moreover, a concomitant reduction in the levels of plasminogen and tissue plasminogen activator messenger RNA was detected as well as an increment in neuroserpin expression; enzymes that partake in proNGF maturation. Human Down's syndrome brains also exhibited elevated zymogenic activity of matrix metalloproteinase 9 (MMP9), the major NGF-degrading protease. These findings indicate a failure in NGF precursor maturation in Down's syndrome brains and a likely enhanced proteolytic degradation of NGF, changes which can compromise the trophic support of the basal forebrain cholinergic neurons.

The formation of inflammatory products may also be responsible of the cholinergic neuron degeneration induced in adult rats by NB injection of preaggregated A $\beta$ . The injection is followed by microglia and astrocyte activation and a strong inflammatory reaction characterized by IL-1 $\beta$  production and an increase of inducible cyclooxygenase and nitric oxide synthase

expression [59]. ProNGF, whose increase was observed in postmortem AD brains [58] and in the hippocampus of subjects with mild cognitive impairment (MCI) and AD [60], has been shown to mediate cell death in PC12 cells [61] and oligodendrocyte cultures [62], through an apoptotic mechanism involving p75(NTR) receptors. Moreover, NB cholinergic neurons, in subjects affected by mild to moderate AD, display a significant down regulation of TrkA, TrkB and TrkC receptor expression during the disease progression whereas no change in p75(NTR) expression was detected [63]. Trk down-regulation was associated with cognitive decline. Mufson et al. [64], observed a significant reduction in the number of TrkA but not p75(NTR) receptor-containing neurons, which co-localize with ChAT, in the MCI and early AD brains, although the number of ChAT-positive neurons in the NB was not significantly different from that in normal subjects. The decrease in TrkA receptor number results in a reduced response of the cholinergic neurons to neurotrophic factors in the initial AD stages. They also observed an increase in proNGF in the cortex of subjects with MCI and early AD. Since proNGF accumulates when there is a low level of cortical TrkA and high level of p75 (NTR) receptors, a shift between molecules facilitating survival and damaging molecules seems to take place in prodromal AD. The degeneration of the forebrain cholinergic neurons may therefore be caused by a decrease in NGF availability and number of Trk binding sites, resulting in a loss of trophic effect, compounded with a proNGF apoptotic effect mediated through the binding to p75(NTR) receptors.

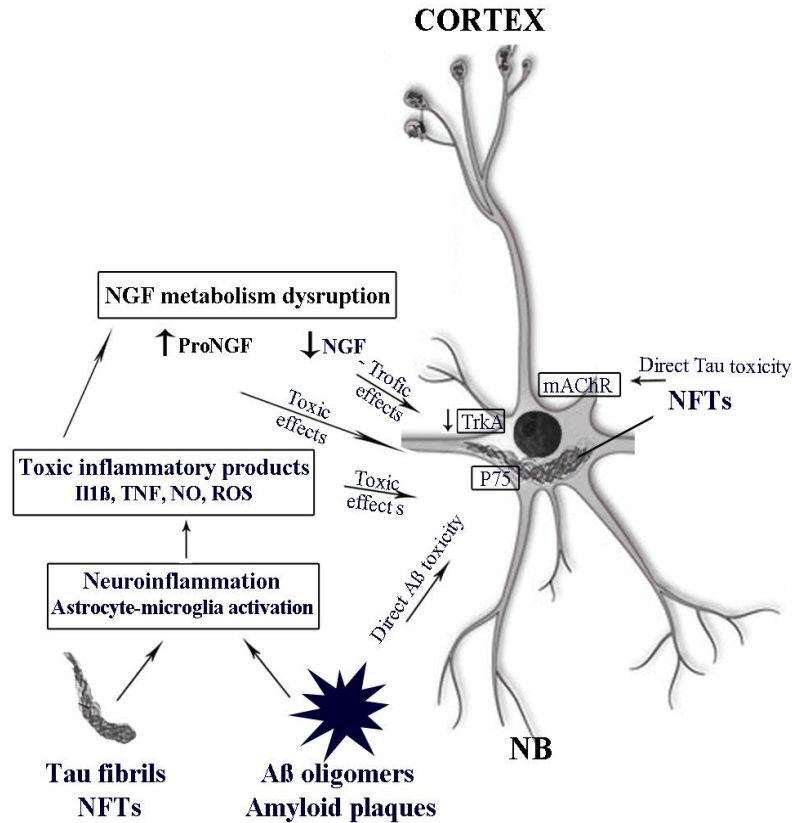
Using rat cortical neurons and NIH-3T3 cell line engineered to stably express p75(NTR), Yaar et al. [65] demonstrated that the A $\beta$  peptide binds to p75(NTR). Furthermore, 3T3 cells expressing p75(NTR), but not wild-type control cells lacking the receptor, undergo apoptosis in the presence of aggregated A $\beta$ . By using neuroblastoma cell clones engineered to express p75(NTR), Perini et al. [66] showed that p75(NTR) is involved in the direct signaling of cell death caused by A $\beta$  via the function of its death domain. This signaling leads to the activation of caspases-8 and -3, the production of reactive oxygen intermediates and the induction of an oxidative stress. They also showed that the direct mechanism of neuronal damage activated by A $\beta$  acts synergistically with the inflammatory reaction induced by A $\beta$ . Indeed, TNF- $\alpha$  and IL-1 $\beta$ , cytokines produced by A $\beta$ -activated

microglia, may potentiate the neurotoxic action of A $\beta$  mediated by p75(NTR) signaling. These results indicate that neurons expressing p75(NTR), if expressing also proinflammatory cytokine receptors, may be preferential targets of the cytotoxic action of A $\beta$  in AD. The authors suggest that the high level of expression of p75(NTR) of the basal forebrain cholinergic neurons may be the reason of their vulnerability in AD, whereas the cholinergic neurons of the brainstem, which do not express p75(NTR), remain undamaged. The deletion of p75(NTR) receptor in a transgenic model of AD (Thy1-hAPP(Lond/Swe) x p75(NTR<sup>-/-</sup>) mice) significantly diminished hippocampal neuritic dystrophy and completely reversed the basal forebrain cholinergic neurite degeneration in comparison with AD mice expressing wild-type p75(NTR). A $\beta$  levels were not affected, suggesting that removal of p75(NTR) extracellular domain reduced the ability of excess A $\beta$  to promote neuritic degeneration [67]. These findings indicate that although p75(NTR) likely does not mediate all A $\beta$  effects, it does play a significant role in enabling A $\beta$ -induced neurodegeneration *in vitro* and *in vivo*. Further references on the interaction between A $\beta$  and p75(NTR) receptors can be found in a recent review [68].

Concluding this paragraph, it may be assumed that neurodegeneration of the cholinergic neurons in AD is caused by an A $\beta$  overload which exerts a direct toxic effect through p75(NTR) and an indirect effect through the inflammatory reaction. The products of neuroinflammation reduce the availability of NGF needed for the cholinergic neurons survival, increase the level of proNGF which in turn exerts a toxic effect on the cholinergic neurons and synergize the toxicity of A $\beta$ . The difference in the expression of p75(NTR) receptors among cholinergic neurons may explain the higher vulnerability of the forebrain cholinergic neurons in comparison with those of the spinal cord and brain stem. The pivotal role of the inflammatory reaction in the degeneration of the cholinergic neurons induced by A $\beta$  is confirmed by the finding that chronic lipopolysaccharide infusions produce a time-dependent, but not dose-dependent, decrease in cortical ChAT activity that parallels a decline in the number of ChAT - and p75(NTR)-immunoreactive cells and a dense

distribution of reactive astrocytes and microglia within the basal forebrain [5]. Moreover, in the rat, the anti-inflammatory drug rofecoxib, a selective cyclooxygenase-2 inhibitor suppresses brain inflammation and protects the forebrain cholinergic neurons from the degeneration induced by A $\beta$  injection into the NB [69].

However, whereas much evidence support a pathogenetic role of NGF metabolism and/or receptor dysfunction in the degeneration of the cholinergic neurons occurring in AD, there is much less information on the mechanism by which neurofibrillary degeneration is involved in the damage and loss of the cholinergic neurons. Yet, the cholinergic lesion in AD is more closely related to fibrillary tau deposition than to the amyloid plaques [20]. Vana et al. [39] observed, by mean of double staining for visualizing phosphorylated tau protein and p75(NTR) expressing cells in tissues from subjects with no cognitive impairment, MCI and AD that the increase in the number of NB neurons showing accumulation of tau protein was accompanied by a decrease in the number of cholinergic neurons identified by p75(NTR) immunostaining. The possibility that an indirect NGF deficit may be caused by neurofibrillary degeneration is supported by the findings of Belarbi et al. [70]. In the THY-Tau22 transgenic mouse model exhibiting a major hippocampal AD-like tau pathology and hyperphosphorylated tau species in the septohippocampal pathway, they observed a loss of cholinergic neurons in the septum, an impairment in reference memory, an alteration in the retrograde axonal transport in the septo-hippocampal pathway and an accumulation of mature NGF in the hippocampus consistent with a decrease in its uptake and axonal transport. A further mechanism is proposed by Simon et al. [71]. According to these authors, extracellular tau binds to M1 and M3 muscarinic receptors leading to an increase in intracellular calcium and cell death. The interaction between tau and muscarinic receptors may also be a way, although not the only one, to explain the spreading of tau pathology occurring in AD. Since, as it will be discussed below, some tauopathies, such as frontal dementia, do not show cholinergic degeneration, the mechanism through which tau deposition contribute to the cholinergic degeneration in AD and some other



**Fig. 1. Aβ and tau fibrils exert direct and indirect toxic effects on the cholinergic neurons. the indirect effects are brought about through the induction of neuroinflammation, the subsequent production of toxic inflammatory products and the disruption of NGF metabolism. abbreviations: mAChR: muscarinic receptor; NB: nucleus basalis; NFTs: neurofibrillary tangles; ROS: reactive oxygen species**

neurodegenerative diseases must be multifactorial and deserves further investigations. In Fig. 1 the different possible mechanisms causing degeneration of the NB cholinergic neurons in AD are schematically summarized.

Finally, it is pertinent to remind that although the degeneration of the cholinergic neurons is an important and characteristic feature of AD, it is associated with a diffuse neuronal damage and synaptic loss [23,72] involving other neurotransmitter systems [73-75] presumably caused by Aβ peptide and neurofibrillary tangle toxicity acting directly and indirectly through the products of the associated inflammatory reaction. It must be also mentioned that, according to some authors (see ref. in [76,77]), early age-associated mitochondria dysfunctions could be upstream of the Aβ cascade. Moreover, Aβ in turn could cause mitochondrial dysfunction,

triggering a vicious circle [78]. However, although plausible, these hypothesis do not explain the selective vulnerability of the forebrain cholinergic neurons.

### 3.2 Other Dementias

#### 3.2.1 Parkinson's disease (PD)

Although the main symptoms of PD involve the motor system, this neurodegenerative disease may present also non motor symptoms including cognitive deficits and dementia. Dementia in PD subjects is sporadic and may begin one or more years after the onset of the motor symptoms.

The degeneration of the dopaminergic neurons located in the substantia nigra is the characteristic pathogenetic feature of PD [79]. However, a loss of cells in the NB was also

described by Whitehouse et al. [80] in postmortem brains of 12 subjects affected by PD and this finding was repeatedly confirmed (see ref. in [81,82]). A cholinergic denervation was observed in PD subjects by neuroimaging techniques using ligands for VAcHT and AChE (see ref. in [83,84]). A denervation of the limbic archicortex in PD patients was demonstrated by positron emission tomography (PET) using [<sup>11</sup>C] methyl-4-piperidiny propionate to visualize AChE and the level of denervation correlated with olfactory dysfunction [85]. A thalamic cholinergic denervation was demonstrated [86] in subjects affected by PD, PD with dementia (PDD) and Lewy body dementia (LBD) but not in AD. Hilker et al. [87] reported a significant reduction of cortical AChE in PD without dementia and a severe reduction in PD with dementia.

In addition to the Lewy bodies (LB), which are clump of  $\alpha$ synuclein and ubiquitin proteins, detectable in the neurons by *post mortem* brain histology [88-90], which play an important pathogenetic role in PD neuronal degeneration, a moderate A $\beta$  load was demonstrated *in vivo* by [<sup>11</sup>C] PIB PET in the cortex and subcortical structure in PD brains [91].

### **3.2.2 Lewy Bodies Dementia (LBD)**

The development of severe cognitive deficits before or together with the motor symptoms is a characteristic feature of LBD. LBD is a type of dementia closely related to both AD and PD. It is anatomically characterized by the presence of Lewy bodies and by a heavy A $\beta$  load, as demonstrated *in vivo* by PET visualization [91]. Two forms are described, the AD variant with Lewy Bodies and the diffuse LBD. In both forms a marked decrease, up to 75%, in ChAT activity in midfrontal cerebral cortex and in hippocampus was observed [81]. The loss of ChAT activity is less severe and occurs later in the clinical course of AD than in LBD in which ChAT loss is already prominent in the earliest stages of illness [92].

In *post mortem* brains of LBD subjects, as well in subjects with multiple system atrophy, a significant loss of cholinergic neurons was detected by Schmeichel et al. [93] in the pedunculo pontine nucleus (PPN) and the laterodorsal tegmental nuclei (Ch5, Ch6) which are spared in AD. The degeneration of the Ch5 and Ch6 cholinergic nuclei leads to the cholinergic denervation of the thalamus observed in LBD and PD but not in AD by Kotagal et al. [86] by measuring PPN-thalamic AChE activity by PET imaging.

### **3.2.3 Atypical parkinsonian diseases**

A cholinergic deficit has been also observed in atypical parkinsonian diseases. Tagliavini et al. [94] and other authors (see ref. in [82]) reported a significant loss of neurons in the NB in subjects affected by progressive supranuclear palsy (PSP). This disease, characterized by clinical features including extrapyramidal symptoms, ocular dyscontrol and cognitive impairment, is considered a tauopathy for the extensive neurofibrillary cluster of phosphorylated tau protein detected in the brains [95]. VAcHT expressions and ChAT activities in caudate nucleus and putamen were also found to be markedly decreased in postmortem brains of subjects with PSP, consistent with a selective loss of striatal cholinergic interneurons [96].

Shinotoh et al. [97] reported a modest reduction in cortical AChE activity in patients with PSP, smaller than in PD subjects and a 38% reduction in the thalamus. The latter indicates a significant loss of brainstem cholinergic PPN neurons. Therefore, it appears that in this atypical parkinsonian disease there is a widespread alteration of the cholinergic neurons involving the forebrain nuclei, striatal interneurons and brain stem nuclei.

The corticobasal syndrome also belongs to the atypical parkinsonian diseases and shows a decrease in AChE activity, demonstrated by neuroimaging. The decrease was observed in the paracentral region and the frontal, parietal and occipital cortices [97,98] which are projection areas of the NB cholinergic neurons. At variance with PSP, with which the corticobasal syndrome is frequently confused [99], no reduction in thalamic AChE activity was detected. Both diseases are defined tauopathies and are characterized by neurofibrillary pathology.

The frontotemporal dementias, which represent in prevalence the second group of senile dementias [100] are also characterized by neurofibrillary pathology. However, no decrease in cortical or thalamic AChE was observed by neuroimaging [98]. They are characterized by personality and behavior disturbances and limited memory loss and present several variants on the basis of the nature of the characteristic protein inclusions [101]. Pick's disease is included in the frontotemporal dementias [102]. The studies of the cholinergic neurons of the NB report contrasting findings [82] ranging from no loss of cholinergic neurons to a 70% decrease.



However, according to Hansen et al. [103], ChAT levels were normal in 5 cases of Pick's disease whereas they were reduced in AD cases studied by comparison.

### **3.2.4 Mechanisms responsible of the degeneration of the cholinergic neurons in parkinson's disease and atypical parkinsonian diseases**

As described above, in AD the loss of cholinergic neurons is confined to the cholinergic forebrain nuclei and according to the most likely hypothesis, their degeneration results from a dysregulation of NGF formation and metabolism caused by direct A $\beta$  toxicity and the associated extensive inflammatory response [56,57,64]. The degeneration of the cholinergic neurons in PD and the other neurodegenerative diseases which share the presence of tau neurofibrils, neurofibrillary tangles and Lewy bodies, shows different patterns. In PD, PD with dementia and LBD there is a loss of forebrain cholinergic neurons [81,82,87] which may be caused by the presence of an A $\beta$  load and A $\beta$  plaques, particularly in LBD, through the mechanisms discussed above. However, in PD and LBD there is a degeneration of the midbrain cholinergic neurons located in Ch5 and Ch6 [93] and a thalamic cholinergic denervation which do not occur in AD. The midbrain cholinergic neurons do not express NGF receptors [41] and do not depend on NGF supply. In PSP, besides the loss of the forebrain and midbrain cholinergic neurons, a degeneration of the striatal cholinergic interneurons was described [96]. Therefore, different mechanisms must be responsible for the degeneration of the cholinergic neurons located in different brain regions. Finally, the frontotemporal dementias, including Pick's disease, do not show a consistent loss of forebrain cholinergic neurons and a significant cortical and thalamic cholinergic denervation. The fronto-temporal dementias are tauopathies characterized by neurofibrillary deposits, but it appears that tau deposition alone is not sufficient to induce the degeneration of the cholinergic neurons, even if tau neurotoxicity has been well documented in hippocampal organotypic slice cultures [104]. Indeed, no obvious differences in the distribution and density of cholinergic and monoaminergic neurons were found comparing tau filament-forming transgenic mice with wild type mice [105]. Conversely, in A30P mice,  $\alpha$ -synuclein-expressing transgenic strain, a degeneration of the forebrain cholinergic neurons was observed after dopamine depletion

induced by 1-methyl-4-phenyl-1,2,3,6-tetrahydropyridine (MPTP) administration [106]. This observation was confirmed and extended by Szego et al. [107] who reported that the number of neurons expressing a cholinergic marker in the medial septum-diagonal band of Broca complex decreases in the  $\alpha$ -synuclein-expressing mice during aging. The decrease is associated with a lower AChE fiber density in the dentate gyrus and in the hippocampal CA1 field. After inducing dopamine depletion by MPTP, a delayed loss of cholinergic neurons and AChE-positive fibers was observed, which was attenuated by L-3,4-dihydroxyphenylalanine (DOPA) treatment. However, P301L tau transgenic pR5 mice, overexpressing  $\alpha$ -synuclein, develop neurofibrillary lesions but do not show the degeneration of basal forebrain cholinergic neurons observed in AD [108]. It appears that  $\alpha$ -synuclein toxicity for the cholinergic neurons is reinforced by age and dopamine depletion, a situation occurring in PD and parkinsonian diseases and therefore  $\alpha$  synuclein seems to be co-responsible for the degeneration of the midbrain cholinergic neurons and to contribute to that of the forebrain neurons.

### **3.2.5 Alcoholic dementia**

Chronic ethanol abuse may lead to alcoholic dementia and the related Korsakoff's syndrome and Wernicke's encephalopathy (WE), whose cognitive deficits mimic AD. The first observation of a loss of cholinergic neurons in the NB of subjects affected by Korsakoff's syndrome was made by Arendt et al. [109]. No significant decrease in the number of cholinergic neurons was found in chronic alcoholism without dementia. The loss of cholinergic neurons concurs with the large decrease in ChAT activity detected in the cortex, hippocampus and cerebellum of subjects with alcoholic dementia by [110]. The degeneration of the cholinergic neurons caused by ethanol abuse can be reproduced in the rat. After 6 months of ethanol intake, a loss of cholinergic neurons, affecting the forebrain nuclei but sparing the brain stem Ch5 and Ch6 nuclei, was observed by Arendt et al. [111] and was accompanied by a decrease in AChE activity in the cerebral cortex, hippocampus and amygdala which indicates a cholinergic denervation. In rats drinking ethanol for 6 months, the decrease in ChAT activity and ACh release in the cortex and hippocampus, together with cognitive impairment, was still observed after four week withdrawal [112]. Investigating the mechanism of the neuronal

degeneration induced by ethanol abuse, Cullen and Halliday [113] observed that in chronic alcoholics with thiamine deficiency, neurofibrillary pathology was found in the NB, but in no other brain regions. Neurofibrillary tangles were not seen in age-matched controls and were infrequent in alcoholics without neuropathological signs of thiamine-deficiency. Neurofibrillary tangles were most numerous in the cases showing NB cell loss. The authors concluded that NB neurodegeneration in chronic alcoholics proceeds through the formation of neurofibrillary tangles. Extending their investigations, Cullen and Halliday, [114] observed that tau-positive granular and fibrillary inclusions were frequent within the magnocellular neurons of the NB in WE subjects, occasional in non-WE alcoholics, and absent in controls. Tau immunoreactivity was not observed in cortical, brainstem, diencephalic or non-cholinergic forebrain structures. The majority of neurons in the basal forebrain showed an increased peroxidase activity in all WE alcoholics and in some NB neurons of non-WE alcoholics, but was rarely seen in controls. These results suggest a link between peroxidase activity and the abnormal accumulation of phosphorylated tau. It should also be mentioned that thiamine deficiency is a common consequence of alcohol abuse and the impairment of ACh synthesis caused by thiamine deficiency was demonstrated since a long time [115]. Thiamine deficiency is therefore an important factor in the dysfunction of the cholinergic neurons in alcoholic dementia. However, it does not explain why the degeneration occurs almost exclusively in the Ch1–Ch4 nuclei. The involvement of players contributing to cholinergic degeneration in other neurodegenerative disease, such as neuroinflammation and NGF dysfunction, may be hypothesized. In organotypic brain slices of NB exposed to ethanol, NGF and the inhibition of MAPK p38 and NOS protected the cholinergic neurons against the ethanol-induced effect [116] confirming the complexity of the mechanism leading to cholinergic cell degeneration in this pathology.

#### **4. CONSEQUENCES OF THE DEGENERATION OF THE BRAIN CHOLINERGIC SYSTEM**

The most evident consequence of the degeneration of the forebrain cholinergic system is a cognitive deficit. More than thirty years ago Drachman [117] asked in a seminal paper, whether the cholinergic system had a specific

role in memory and cognitive functions in man. Shortly later, the cholinergic hypothesis of geriatric memory dysfunction [24] was proposed and was followed by countless papers investigating and demonstrating the role of the cholinergic system in learning and memory. An analysis of these papers is beyond the scope of this article and therefore the reader is referred to a few recent reviews [118-122]. ACh in the brain alters neuronal excitability, influences synaptic transmission, induces synaptic plasticity and coordinates firing of groups of neurons. As a result, it changes the state of neuronal networks throughout the brain and modifies their response to internal and external inputs [123]. The administration of anticholinergic drugs to humans and animals, the use of cholinergic receptor knockout mice and the lesioning of the forebrain cholinergic neurons in animals result in deficit of attention, impairment in information acquisition and amnesia. Since dementias are characterized by multiple cognitive deficits including the impairment of memory [124], it may be assumed that the loss of forebrain cholinergic neurons is largely responsible for the cognitive deficits of dementias. On this assumption, cholinesterase inhibitors are used as therapeutic agents in AD with the aim to enhance the residual cholinergic function [125].

In PD and LBD a degeneration of the midbrain cholinergic neurons located in the Ch5 and Ch6 nuclei was observed, with or without the concomitant loss of Ch1–Ch4 neurons. The midbrain cholinergic neurons innervate the spinal cord, brain stem, thalamus, hypothalamus, basal forebrain and medial frontal cortex and are involved in motor activity, arousal and attention, the sleep-wakefulness cycle, the regulation of muscular tone during REM sleep [119]. Their loss may contribute to mobility impairment [84] and be a cause of the sleep behavior disorders in LB dementia [93].

Since the first observation in transfected cultured cells [126] that stimulation of M1 and M3 muscarinic receptor subtypes increased the basal secretion of amyloid precursor protein (APP), the possible role of the brain cholinergic system in the regulation of A $\beta$  peptide metabolism has been the object of much investigations (see ref. in [34]). Experiments “in vitro” and in murine AD models showed that M1 receptors have a role in APP secretion via  $\alpha$ -secretase activation and in decreasing A $\beta$  levels, via  $\beta$ -secretase inhibition [127]. Therefore it has been assumed that in AD the degeneration of the

cholinergic neurons, with the ensuing cholinergic hypofunction, may aggravate the A $\beta$  overload which is considered a main pathogenetic mechanism.

## 5. CONCLUSION

The first question asked in the Introduction was about which nuclei of the cholinergic system degenerate in different neurodegenerative disease. The answer is that there are remarkable differences among diseases. In AD there is a progressive degeneration of the forebrain cholinergic neurons, leading to a cholinergic denervation of the cortical mantle and hippocampus, whereas the cholinergic neurons of the brain stem and spinal cord are spared. In LBD the rapid and severe degeneration of the cholinergic forebrain neurons also involves the brain stem cholinergic nuclei resulting in a denervation of the thalamus besides the cortex. In some of the atypical Parkinsonian diseases, a degeneration of the cholinergic neurons in the caudate nucleus and putamen was also detected. In PD a degeneration of the forebrain cholinergic neurons occurs in cases with dementia. In alcoholic dementia a degeneration of the cholinergic neurons, confined to the forebrain nuclei, was found. In all these neurodegenerative diseases, the loss of the forebrain cholinergic neurons is associated with dementia, strongly indicating a role in the cognitive processes of the neurons located in the Ch1–Ch4 nuclei.

The different degeneration patterns of the cholinergic neurons observed in the neurodegenerative diseases lead to ask which are the reasons of the differences. The pathogenetic mechanisms of the neurodegenerative diseases are not yet fully understood but three culprits stand out, A $\beta$  deposition, tau fibrillary tangles and the synuclein-containing Lewy Bodies. A $\beta$  deposition and tau fibrillary tangles are present in AD, PD with dementia and LBD. Lewy Bodies are present in PD and LBD. A genetic and age related mitochondrial dysfunction has been also proposed as a possible common upstream cause of AD, PD and other neurodegenerative diseases [128]. Neuroinflammation, developing particularly in AD, but present in all neurodegenerative diseases, is a further pathogenetic factor. The finding that in frontoparietal dementias, which are typical tauopathies, there is no degeneration of the cholinergic neurons suggests that neurofibrillary deposition alone is not sufficient to

damage the cholinergic neurons. Much evidence demonstrates that A $\beta$  is toxic for the cholinergic neurons. However, not all cholinergic nuclei are affected in AD but only the forebrain neurons. Their vulnerability in AD has been attributed to the fact that they are continuously dependent on NGF for the preservation of their phenotype and function. Differences in NGF receptor expression, a dysregulation in NGF formation and metabolism, resulting from the joint toxicities of A $\beta$  and inflammatory products, are the factors whose interplay is presently considered responsible for the degeneration of the cholinergic neurons in AD. However, the possible contribution of tau fibrils in this complex picture needs to be considered and investigated. Moreover, a definite mechanism explaining the loss of the midbrain cholinergic neurons in LBD and PD has not yet been found.

In conclusion, our review shows that three decades of investigations provide an ample histopathological description of the loss of the cholinergic neurons in different neurodegenerative diseases and its behavioral consequences. However, the pathological mechanisms responsible for their degeneration are only beginning to be unraveled.

## ACKNOWLEDGEMENTS

The work was supported by the University of Florence and the Ente Cassa di Risparmio di Firenze, grants ECRF 2010.0312 and 2011.0395.

## ETHICAL APPROVAL

The authors declare that there are no ethical issues involved in this review.

## COMPETING INTERESTS

Authors have declared that no competing interests exist.

## REFERENCES

1. Wyss-Coray T, Mucke L. Inflammation in neurodegenerative disease--a double-edged sword. *Neuron*. 2002;35:419-432. DOI:10.1016/S0896-6273(02)00794-8. PMID: 12165466.
2. Varnum MM, Ikezu T. The classification of microglial activation phenotypes on

- neurodegeneration and regeneration in Alzheimer's disease brain. *Arch. Immunol. Ther. Exp. (Warsz.)*. 2012;60:251-266. DOI:10.1007/s00005-012-0181-2. PMID:22710659.
3. Mosher KI, Wyss-Coray T. Microglial dysfunction in brain aging and Alzheimer's disease. *Biochem. Pharmacol.* 2014;88:594-604. DOI:10.1016/j.bcp.2014.01.008. PMID:24445162.
  4. Olton DS, Wenk G. Dementia: Animal models of the cognitive impairments produced by degeneration of the basal forebrain cholinergic system. In: *Psychopharmacology. The third generation of progress*. Meltzer HY ed. Raven Press New York. 1987;941-954.
  5. Willard LB, Hauss-Wegrzyniak B, Wenk GL. Pathological and biochemical consequences of acute and chronic neuroinflammation within the basal forebrain cholinergic system of rats. *Neuroscience*. 1999;88:193-200. DOI:10.1016/S0306-4522(98)00216-4. PMID:10051200.
  6. Mantione CR, Fisher A, Hanin I. The AF64a-treated mouse: Possible model for central cholinergic hypofunction. *Science*. 1981;213:579-580. DOI:10.1126/science.6894649. PMID:6894649.
  7. Wiley RG, Oeltmann TN, Lappi DA. Immunolesioning: Selective destruction of neurons using immunotoxin to rat NGF receptor. *Brain Res*. 1991;562:149-153. DOI:10.1016/0006-8993(91)91199-B. PMID:1666014.
  8. Ballmaier M, Casamenti F, Zoli M, Pepeu G, Spano P. Selective immunolesioning of cholinergic neurons in nucleus basalis magnocellularis impairs prepulse inhibition of acoustic startle. *Neuroscience*. 2001;108:299-305. DOI: 10.1016/S0306-4522(01)00413-4. PMID: 11734362.
  9. Pienaar IS, Harrison IF, Elson JL, Bury A, Woll P, Simon AK, et al. An animal model mimicking pedunclopontine nucleus cholinergic degeneration in Parkinson's disease. *Brain Struct. Funct*; 2013. DOI 10.1007/s00429-013-0669-5. PMID:24292256.
  10. Rinne JO, Ma SY, Lee MS, Collan Y, Roytta M. Loss of cholinergic neurons in the pedunclopontine nucleus in Parkinson's disease is related to disability of the patients. *Parkinsonism. Relat Disord*. 2008;14:553-557. DOI:10.1016/j.parkreldis.2008.01.006. PMID:18329941.
  11. Whitehouse PJ, Price DL, Struble RG, Clark AW, Coyle JT, Delon MR. Alzheimer's disease and senile dementia: Loss of neurons in the basal forebrain. *Science*. 1982;215:1237-1239. DOI:10.1126/science.7058341. PMID:7058341.
  12. Hornykiewicz O. Pharmacology and pathophysiology of dopaminergic neurons. *Adv. Cytopharmacol.* 1971;1:369-377. PMID: 4950404.
  13. Schliebs R, Arendt T. The cholinergic system in aging and neuronal degeneration. *Behav. Brain Res*. 2011;221:555-563. DOI:10.1016/j.bbr.2010.11.058. PMID:21145918.
  14. Kimura H, McGeer PL, Peng JH, McGeer EG. The central cholinergic system studied by choline acetyltransferase immunohistochemistry in the cat. *J. Comp Neurol*. 1981;200:151-201. PMID:7287919.
  15. Fibiger HC. The organization and some projections of cholinergic neurons of the mammalian forebrain. *Brain Res*. 1982;257:327-388. PMID: 6756546.
  16. Mesulam MM, Mufson EJ, Levey AI, Wainer BH. Cholinergic innervation of cortex by the basal forebrain: Cytochemistry and cortical connections of the septal area, diagonal band nuclei, nucleus basalis (substantia innominata) and hypothalamus in the rhesus monkey. *J. Comp Neurol*. 1983;214:170-197. PMID:6841683.
  17. Levey AI, Wainer BH, Rye DB, Mufson EJ, Mesulam MM. Choline acetyltransferase-immunoreactive neurons intrinsic to rodent cortex and distinction from acetylcholinesterase-positive neurons. *Neuroscience*. 1984;13:341-353. PMID:6514183.
  18. Mufson EJ, Benoit R, Mesulam MM. Immunohistochemical evidence for a possible somatostatin-containing amygdalostriatal pathway in normal and Alzheimer's disease brain. *Brain Res*.

- 1988;453:117-128. DOI: 10.1016/0006-8993(88)90149-7. PMID: 2900053.
19. Wu H, Williams J, Nathans J. Complete morphologies of basal forebrain cholinergic neurons in the mouse. *Elife*. 2014;3:e02444. DOI: 10.7554/eLife.02444. PMID: 24894464.
  20. Mesulam MM. Cholinergic circuitry of the human nucleus basalis and its fate in Alzheimer's disease. *J. Comp Neurol*. 2013;521:4124-4144. DOI:10.1002/cne.23415. PMID: 23852922.
  21. Davies P, Maloney AJ. Selective loss of central cholinergic neurons in Alzheimer's disease. *Lancet*. 1976;2:1403. PMID:63862.
  22. Perry EK, Perry RH, Blessed G, Tomlinson BE. Necropsy evidence of central cholinergic deficits in senile dementia. *Lancet*. 1977;1:189. PMID: 64712.
  23. Hardy J, Adolfsson R, Alafuzoff I, Bucht G, Marcusson J, Nyberg P, et al. Transmitter deficits in Alzheimer's disease. *Neurochem. Int*. 1985;7:545-563. DOI:10.1016/0197-0186(85)90050-6. PMID:20492959.
  24. Bartus RT, Dean RL, III, Beer B, Lippa AS. The cholinergic hypothesis of geriatric memory dysfunction. *Science*. 1982;217:408-414. DOI:10.1126/science.7046051. PMID:7046051.
  25. Nagai T, McGeer PL, Peng JH, McGeer EG, Dolman CE. Choline acetyltransferase immunohistochemistry in brains of Alzheimer's disease patients and controls. *Neurosci. Lett*. 1983;36:195-199. PMID: 6866327.
  26. Pepeu G, Gori G, Antuono P. Changes in brain neurotransmitters during aging and cerebral hypoxia. In drug treatment and prevention in cerebrovascular disorders. Tognoni G, Garattini S, Eds. Elsevier/North Holland Biomedical Press Amsterdam. 1979;3-12.
  27. Efang SM, Garland EM, Staley JK, Khare AB, Mash DC. Vesicular acetylcholine transporter density and Alzheimer's disease. *Neurobiol. Aging*. 1997;18:407-413. DOI: 10.1016/S0197-4580(97)00038-9. PMID: 9330972.
  28. Mash DC, Flynn DD, Potter LT. Loss of M2 muscarine receptors in the cerebral cortex in Alzheimer's disease and experimental cholinergic denervation. *Science*. 1985; 228:1115-1117. DOI:10.1126/science.3992249. PMID:3992249.
  29. Zhang W, Basile AS, Gomeza J, Volpicelli LA, Levey AI, Wess J. Characterization of central inhibitory muscarinic autoreceptors by the use of muscarinic acetylcholine receptor knock-out mice. *J. Neurosci*. 2002;22:1709-1717. PMID: 11880500.
  30. Kuhl DE, Minoshima S, Fessler JA, Frey KA, Foster NL, Ficaró EP, et al. *In vivo* mapping of cholinergic terminals in normal aging, Alzheimer's disease and Parkinson's disease. *Ann. Neurol*. 1996;40:399-410. PMID: 8797529.
  31. Cullen KM, Halliday GM, Double KL, Brooks WS, Creasey H, Broe GA. Cell loss in the nucleus basalis is related to regional cortical atrophy in Alzheimer's disease. *Neuroscience*. 1997;78:641-652. DOI:10.1016/S0306-4522(96)00569-6. PMID:9153647.
  32. Hardy J, Allsop D. Amyloid deposition as the central event in the aetiology of Alzheimer's disease. *Trends Pharmacol. Sci*. 1991;12:383-388. PMID: 1763432.
  33. Hardy JA, Higgins GA. Alzheimers-Disease-the Amyloid Cascade Hypothesis. *Science*. 1992;256:184-185. DOI:10.1126/science.1566067. PMID:1566067.
  34. Pakaski M, Kalman J. Interactions between the amyloid and cholinergic mechanisms in Alzheimer's disease. *Neurochem. Int*. 2008;53:103-111. DOI:10.1016/j.neuint.2008.06.005. PMID:18602955.
  35. Giovannelli L, Casamenti F, Scali C, Bartolini L, Pepeu G. Differential effects of amyloid peptides beta-(1-40) and beta-(25-35) injections into the rat nucleus basalis. *Neuroscience*. 1995;66:781-792. DOI:10.1016/0306-4522(94)00610-H. PMID:7651609.
  36. Bellucci A, Luccarini I, Scali C, Prosperi C, Giovannini MG, Pepeu G, et al. Cholinergic dysfunction, neuronal damage and axonal loss in TgCRND8 mice. *Neurobiol. Dis*. 2006;23:260-272. DOI:10.1016/j.nbd.2006.03.012. PMID:16766197.

37. Geula C, Mesulam MM, Saroff DM, Wu CK. Relationship between plaques, tangles and loss of cortical cholinergic fibers in Alzheimer disease. *J. Neuropathol. Exp. Neurol.* 1998;57:63-75. PMID: 9600198.
38. Mesulam M, Shaw P, Mash D, Weintraub S. Cholinergic nucleus basalis tauopathy emerges early in the aging-MCI-AD continuum. *Ann. Neurol.* 2004;55:815-828. DOI: 10.1002/ana.20100. PMID:15174015.
39. Vana L, Kanaan NM, Ugwu IC, Wu J, Mufson EJ, Binder LI. Progression of tau pathology in cholinergic Basal forebrain neurons in mild cognitive impairment and Alzheimer's disease. *Am. J. Pathol.* 2011;179:2533-2550. DOI:10.1016/j.ajpath.2011.07.044. PMID:21945902.
40. Giacobini E, Gold G. Alzheimer disease therapy--moving from amyloid-beta to tau. *Nat. Rev. Neurol.* 2013;9:677-686. DOI:10.1038/nrneurol.2013.223. PMID:24217510.
41. Woolf NJ, Jacobs RW, Butcher LL. The pontomesencephalotegmental cholinergic system does not degenerate in Alzheimer's disease. *Neurosci. Lett.* 1989;96:277-282. PMID: 2717053.
42. Rossor MN, Garrett NJ, Johnson AL, Mountjoy CQ, Roth M, Iversen LL. A post-mortem study of the cholinergic and GABA systems in senile dementia. *Brain.* 1982;105:313-330. DOI: 10.1093/brain/105.2.313. PMID:7082992.
43. Rossor MN, Svendsen C, Hunt SP, Mountjoy CQ, Roth M, Iversen LL. The substantia innominata in Alzheimer's disease: An histochemical and biochemical study of cholinergic marker enzymes. *Neurosci. Lett.* 1982;28:217-222. DOI:10.1016/0304-3940(82)90155-0. PMID:7070710.
44. Yates CM, Simpson J, Gordon A, Christie JE. Cholinergic enzymes in the spinal cord in Alzheimer-type dementia. *J. Neural Transm. Park Dis. Dement. Sect.* 1989;1:311-315. PMID: 2532018.
45. Sica RE, Pereyra S, Mangone CA. Loss of motor units in Alzheimer's disease. *Electromyogr. Clin. Neurophysiol.* 1998;38:475-479. PMID: 9842482.
46. Richardson PM, Issa VM, Riopelle RJ. Distribution of neuronal receptors for nerve growth factor in the rat. *J. Neurosci.* 1986;6:2312-2321. PMID: 3018191.
47. Kordower JH, Bartus RT, Bothwell M, Schatteman G, Gash DM. Nerve growth factor receptor immunoreactivity in the nonhuman primate (*Cebus apella*): Distribution, morphology and colocalization with cholinergic enzymes. *J. Comp Neurol.* 1988;277:465-486. PMID: 2850304.
48. Pioro EP, Cuello AC. Distribution of nerve growth factor receptor-like immunoreactivity in the adult rat central nervous system. Effect of colchicine and correlation with the cholinergic system--II. Brainstem, cerebellum and spinal cord. *Neuroscience.* 1990;34:89-110. PMID:2158008.
49. Roux PP, Barker PA. Neurotrophin signaling through the p75 neurotrophin receptor. *Prog. Neurobiol.* 2002;67:203-233. DOI: 10.1016/S0301-0082(02)00016-3. PMID: 12169297.
50. Merlio JP, Ernfors P, Jaber M, Persson H. Molecular cloning of rat trkC and distribution of cells expressing messenger RNAs for members of the trk family in the rat central nervous system. *Neuroscience.* 1992;51:513-532. DOI: 10.1016/0306-4522(92)90292-A. PMID: 1488112.
51. Cuello AC. Effects of trophic factors on the CNS cholinergic phenotype. *Prog. Brain Res.* 1996;109:347-358. PMID: 9009722.
52. Ruberti F, Capsoni S, Comparini A, Di Daniel E, Franzot J, Gonfloni S, et al. Phenotypic knockout of nerve growth factor in adult transgenic mice reveals severe deficits in basal forebrain cholinergic neurons, cell death in the spleen and skeletal muscle dystrophy. *J. Neurosci.* 2000;20:2589-2601. PMID:10729339.
53. Fischer W, Victorin K, Bjorklund A, Williams LR, Varon S, Gage FH. Amelioration of cholinergic neuron atrophy and spatial memory impairment in aged rats by nerve growth factor. *Nature.* 1987;329: 65-68. PMID: 3627243.
54. Casamenti F, Scali C, Giovannelli L, Faussone-Pellegrini MS, Pepeu G. Effect of nerve growth factor and GM1 ganglioside on the recovery of cholinergic neurons after a lesion of the nucleus basalis in aging rats. *J. Neural Transm.*

- Park Dis. Dement. Sect. 1994;7:177-193. PMID: 7710670.
55. Mufson EJ, Ikonovic MD, Styren SD, Counts SE, Wu J, Leurgans S, et al. Preservation of brain nerve growth factor in mild cognitive impairment and Alzheimer disease. Arch. Neurol. 2003;60:1143-1148. DOI:10.1001/archneur.60.8.1143. PMID:12925373.
  56. Cuello AC, Bruno MA, Allard S, Leon W, Iulita MF. Cholinergic involvement in Alzheimer's disease. A link with NGF maturation and degradation. J. Mol. Neurosci. 2010;40:230-235. DOI:10.1007/s12031-009-9238-z. PMID:19680822.
  57. Iulita MF, Cuello AC. Nerve growth factor metabolic dysfunction in Alzheimer's disease and Down syndrome. Trends Pharmacol. Sci. 2014;35:338-348. DOI: 10.1016/j.tips.2014.04.010. PMID:24962069.
  58. Bruno MA, Leon WC, Fragoso G, Mushynski WE, Almazan G, Cuello AC. Amyloid beta-induced nerve growth factor dysmetabolism in Alzheimer disease. J. Neuropathol. Exp. Neurol. 2009;68:857-869. DOI:10.1097/NEN.0b013e3181aed9e6. PMID: 19606067.
  59. Giovannini MG, Scali C, Prosperi C, Bellucci A, Vannucchi MG, Rosi S, et al. Beta-amyloid-induced inflammation and cholinergic hypofunction in the rat brain *in vivo*: Involvement of the p38MAPK pathway. Neurobiol. Dis. 2002;11:257-274. DOI:10.1006/nbdi.2002.0538. PMID:12505419.
  60. Mufson EJ, He B, Nadeem M, Perez SE, Counts SE, Leurgans S, et al. Hippocampal proNGF signaling pathways and beta-amyloid levels in mild cognitive impairment and Alzheimer disease. J. Neuropathol. Exp. Neurol. 2012;71:1018-1029. DOI:10.1097/NEN.0b013e318272caa b. PMID: 23095849.
  61. Armugam A, Koh DC, Ching CS, Chandrasekaran K, Kaur P, Jeyaseelan K. Pro-domain in precursor nerve growth factor mediates cell death. Neurochem. Int. 2012;60:852-863. DOI:10.1016/j.neuint.2012.03.006. PMID:22480846.
  62. Beattie MS, Harrington AW, Lee R, Kim JY, Boyce SL, Longo FM, et al. ProNGF induces p75-mediated death of oligodendrocytes following spinal cord injury. Neuron. 2002;36:375-386. PMID:12408842.
  63. Ginsberg SD, Che S, Wu J, Counts SE, Mufson EJ. Down regulation of trk but not p75NTR gene expression in single cholinergic basal forebrain neurons mark the progression of Alzheimer's disease. J. Neurochem. 2006;97:475-487. DOI: 10.1111/j.1471-4159.2006.03764.x. PMID: 16539663.
  64. Mufson EJ, Counts SE, Fahnstock M, Ginsberg SD. Cholinergic molecular substrates of mild cognitive impairment in the elderly. Curr. Alzheimer Res. 2007;4:340-350. DOI: 10.2174/156720507781788855. PMID: 17908035.
  65. Yaar M, Zhai S, Pilch PF, Doyle SM, Eisenhauer PB, Fine RE, et al. Binding of beta-amyloid to the p75 neurotrophin receptor induces apoptosis. A possible mechanism for Alzheimer's disease. J. Clin. Invest. 1997;100:2333-2340. DOI: 10.1172/JCI119772. PMID: 9410912.
  66. Perini G, Della-Bianca V, Politi V, Della VG, Dal Pra I, Rossi F, et al. Role of p75 neurotrophin receptor in the neurotoxicity by beta-amyloid peptides and synergistic effect of inflammatory cytokines. J. Exp. Med. 2002;195:907-918. DOI: 10.1084/jem.20011797. PMID:12505419.
  67. Knowles JK, Rajadas J, Nguyen TV, Yang T, LeMieux MC, Vander GL, et al. The p75 neurotrophin receptor promotes amyloid-beta (1-42)-induced neuritic dystrophy *in vitro* and *in vivo*. J. Neurosci. 2009;29:10627-10637. DOI:10.1523/JNEUROSCI.0620-09.2009. PMID: 19710315.
  68. Patel AN, Jhamandas JH. Neuronal receptors as targets for the action of amyloid-beta protein (A $\beta$ ) in the brain. Expert Rev. Mol. Med. 2012;14:e2. DOI: 10.1017/S1462399411002134. PMID: 22261393.
  69. Giovannini MG, Scali C, Prosperi C, Bellucci A, Pepeu G, Casamenti F. Experimental brain inflammation and neurodegeneration as model of Alzheimer's disease: Protective effects of selective COX-2 inhibitors. Int. J.

- Immunopathol. Pharmacol. 2003;16:31-40. PMID: 14552702.
70. Belarbi K, Burnouf S, Fernandez-Gomez FJ, Desmercières J, Troquier L, Brouillette J, et al. Loss of medial septum cholinergic neurons in THY-Tau22 mouse model: What links with tau pathology? *Curr. Alzheimer Res.* 2011;8:633-638. DOI: 10.2174/156720511796717230. PMID: 21605043.
71. Simon D, Hernandez F, Avila J. The involvement of cholinergic neurons in the spreading of tau pathology. *Front Neurol.* 2013;4:74. DOI:10.3389/fneur.2013.00074. PMID: 23785352.
72. Hamos JE, DeGennaro LJ, Drachman DA. Synaptic loss in Alzheimer's disease and other dementias. *Neurology.* 1989;39:355-361. PMID: 2927643.
73. Zweig RM, Ross CA, Hedreen JC, Steele C, Cardillo JE, Whitehouse PJ, et al. The neuropathology of aminergic nuclei in Alzheimer's disease. *Ann. Neurol.* 1988;24:233-242. PMID: 3178178.
74. Halliday GM, McCann HL, Pamphlett R, Brooks WS, Creasey H, McCusker E, et al. Brain stem serotonin-synthesizing neurons in Alzheimer's disease: A clinicopathological correlation. *Acta Neuropathol.* 1992;84:638-650. PMID:1281956.
75. Lai MKP, Ramirez KJ, Tsang SWY, Francis P. Alzheimer's disease as a neurotransmitter disease. In: Dawbarn D and Allen SJ Eds *Neurobiology of Alzheimer's disease.* Oxford University Press, Oxford. 2007;244-282.
76. Piaceri I, Rinnoci V, Bagnoli S, Failli Y, Sorbi S. Mitochondria and Alzheimer's disease. *J. Neurol. Sci.* 2012;322:31-34. DOI:10.1016/J.JNS.2012.05.033. PMID:22694975.
77. Leuner K, Muller WE, Reichert AS. From Mitochondrial dysfunction to amyloid beta formation: Novel insights into the pathogenesis of Alzheimer's disease. *Mol. Neurobiol.* 2012;46:186-193. DOI: 10.1007/S12035-012-8307-4. PMID: 22833458.
78. Morley JE, Farr SA. The role of amyloid-beta in the regulation of memory. *Biochem. Pharmacol.* 2014;88:479-485. DOI:10.1016/J.BCP.2013.12.018. PMID:24398426.
79. Bernheimer H, Birkmayer W, Hornykiewicz O, Jellinger K, Seitelberger F. Brain dopamine and the syndromes of Parkinson and Huntington. Clinical, morphological and neurochemical correlations. *J. Neurol. Sci.* 1973;20:415-455. PMID: 4272516.
80. Whitehouse PJ, Hedreen JC, White CL, III, Price DL. Basal forebrain neurons in the dementia of Parkinson disease. *Ann. Neurol.* 1983;13:243-248. PMID: 6847136.
81. Tiraboschi P, Hansen LA, Alford M, Sabbagh MN, Schoos B, Masliah E, et al. Cholinergic dysfunction in diseases with Lewy bodies. *Neurology.* 2000;54:407-411. PMID: 10668703.
82. Bigl V, Arendt T, Biesold D. The nucleus basalis of Meynert during ageing and in dementing neuropsychiatric disorders. In: Steriade M, Biesold D, Eds. *Brain cholinergic systems.* Oxford University Press, Oxford. 1990;364-386.
83. Bohnen NI, Albin RL. The cholinergic system and Parkinson disease. *Behav. Brain Res.* 2011;221:564-573. DOI:10.1016/j.bbr.2009.12.048. PMID:20060022.
84. Muller ML, Bohnen NI. Cholinergic dysfunction in Parkinson's disease. *Curr. Neurol. Neurosci. Rep.* 2013;13:377. DOI:10.1007/s11910-013-0377-9. PMID:23943367.
85. Bohnen NI, Muller ML, Kotagal V, Koeppe RA, Kilbourn MA, Albin RL, et al. Olfactory dysfunction, central cholinergic integrity and cognitive impairment in Parkinson's disease. *Brain.* 2010;133:1747-1754. DOI:10.1093/brain/awq079. PMID:20413575.
86. Kotagal V, Muller ML, Kaufer DI, Koeppe RA, Bohnen NI. Thalamic cholinergic innervation is spared in Alzheimer disease compared to parkinsonian disorders. *Neurosci. Lett.* 2012;514:169-172. DOI:10.1016/j.neulet.2012.02.083. PMID:22414859.
87. Hilker R, Thomas AV, Klein JC, Weisenbach S, Kalbe E, Burghaus L, et al. Dementia in Parkinson disease: Functional imaging of cholinergic and dopaminergic pathways. *Neurology.* 2005;65:1716-1722. PMID: 16344512.



88. Kalra S, Bergeron C, Lang AE. Lewy body disease and dementia. A review. *Arch. Intern. Med.* 1996;156:487-493. DOI: 10.1001/archinte.1996.00440050031004. PMID: 8604954.
89. Perry R, McKeith I, Perry E. Lewy body dementia--clinical, pathological and neurochemical interconnections. *J. Neural Transm. Suppl.* 1997;51:95-109. PMID:9470131.
90. Spillantini MG. Parkinson's disease, dementia with Lewy bodies and multiple system atrophy are alpha-synucleinopathies. *Parkinsonism. Relat Disord.* 1999;5:157-162. DOI:10.1016/S1353-8020(99)00031-0. PMID:18591134.
91. Edison P, Rowe CC, Rinne JO, Ng S, Ahmed I, Kempainen N, et al. Amyloid load in Parkinson's disease dementia and Lewy body dementia measured with [11C] PIB positron emission tomography. *J. Neurol. Neurosurg. Psychiatry.* 2008;79:1331-1338. DOI:10.1136/jnnp.2007.127878. PMID:18653550.
92. Tiraboschi P, Hansen LA, Alford M, Merdes A, Masliah E, Thal LJ, et al. Early and widespread cholinergic losses differentiate dementia with Lewy bodies from Alzheimer disease. *Arch. Gen. Psychiatry.* 2002;59:946-951. DOI:10.1001/archpsyc.59.10.946. PMID:12365882.
93. Schmeichel AM, Buchhalter LC, Low PA, Parisi JE, Boeve BW, Sandroni P, et al. Mesopontine cholinergic neuron involvement in Lewy body dementia and multiple system atrophy. *Neurology.* 2008;70:368-373. DOI:10.1212/01.wnl.0000298691.71637.96. PMID: 18227417.
94. Tagliavini F, Pilleri G, Bouras C, Constantinidis J. The basal nucleus of Meynert in patients with progressive supranuclear palsy. *Neurosci. Lett.* 1984;44:37-42. PMID: 6717850.
95. Boeve BF. Progressive supranuclear palsy. *Parkinsonism. Relat Disord.* 2012;18(Suppl1):192-S194. DOI:10.1016/S1353-8020(11)70060-8. PMID:22166432.
96. Suzuki M, Desmond TJ, Albin RL, Frey KA. Cholinergic vesicular transporters in progressive supranuclear palsy. *Neurology.* 2002;58:1013-1018. PMID:11940684.
97. Shinotoh H, Namba H, Yamaguchi M, Fukushi K, Nagatsuka S, Iyo M, et al. Positron emission tomographic measurement of acetylcholinesterase activity reveals differential loss of ascending cholinergic systems in Parkinson's disease and progressive supranuclear palsy. *Ann. Neurol.* 1999;46:62-69. PMID: 10401781.
98. Hirano S, Shinotoh H, Shimada H, Aotsuka A, Tanaka N, Ota T, et al. Cholinergic imaging in corticobasal syndrome, progressive supranuclear palsy and frontotemporal dementia. *Brain.* 2010;133:2058-2068. DOI:10.1093/brain/awq120. PMID:20558417.
99. Strupp M. Corticobasal syndrome: A field of uncertainty. *J. Neurol.* 2011;258:173-175. DOI: 10.1007/s00415-010-5874-z. PMID: 21165636.
100. Snowden JS, Neary D, Mann DM. Frontotemporal dementia. *Br. J. Psychiatry.* 2002;180:140-143. DOI: 10.1192/bjp.180.2.140. PMID: 11823324.
101. Goedert M, Ghetti B, Spillantini MG. Frontotemporal dementia: Implications for understanding Alzheimer disease. *Cold Spring Harb. Perspect. Med.* 2012;2:a006254. DOI:10.1101/cshperspect.a006254. PMID:22355793.
102. Kertesz A. Frontotemporal dementia/Pick's disease. *Arch. Neurol.* 2004;61:969-971. DOI: 10.1001/archneur.61.6.969. PMID:15210543.
103. Hansen LA, Deteresa R, Tobias H, Alford M, Terry RD. Neocortical morphometry and cholinergic neurochemistry in Pick's disease. *Am. J. Pathol.* 1988;131:507-518. PMID: 3381880.
104. Messing L, Decker JM, Joseph M, Mandelkow E, Mandelkow EM. Cascade of tau toxicity in inducible hippocampal brain slices and prevention by aggregation inhibitors. *Neurobiol. Aging.* 2013;34:1343-1354. DOI:10.1016/j.neurobiolaging.2012.10.024. PMID: 23158765.
105. Morcinek K, Kohler C, Gotz J, Schroder H. Pattern of tau hyperphosphorylation and neurotransmitter markers in the brainstem

- of senescent tau filament forming transgenic mice. *Brain Res.* 2013;1497:73-84. DOI: 10.1016/j.brainres.2012.12.016. PMID: 23261664.
106. Szego EM, Gerhardt E, Outeiro TF, Kermer P. Dopamine-depletion and increased alpha-synuclein load induce degeneration of cortical cholinergic fibers in mice. *J. Neurol. Sci.* 2011;310:90-95. DOI:10.1016/j.jns.2011.06.048. PMID:21774947.
  107. Szego EM, Outeiro TF, Kermer P, Schulz JB. Impairment of the septal cholinergic neurons in MPTP-treated A30P alpha-synuclein mice. *Neurobiol. Aging.* 2013;34:589-601. DOI:10.1016/j.neurobiolaging.2012.04.012. PMID: 22579457.
  108. Kohler C, Bista P, Gotz J, Schroder H. Analysis of the cholinergic pathology in the P301L tau transgenic pR5 model of tauopathy. *Brain Res.* 2010;1347:111-124. DOI: 10.1016/j.brainres.2010.05.076. PMID: 20513372.
  109. Arendt T, Bigl V, Arendt A, Tennstedt A. Loss of neurons in the nucleus basalis of Meynert in Alzheimer's disease, paralysis agitans and Korsakoff's Disease. *Acta Neuropathol.* 1983;61:101-108. PMID:6637393.
  110. Antuono P, Sorbi S, Bracco L, Fusco T, Amaducci L. A discrete sampling technique in senile dementia of the Alzheimer type and alcoholic dementia: Study of the cholinergic system. Amaducci L, Davison AN, Antuono P Eds *Aging of the brain and dementia.* Raven Press, New York. 1980;151-158.
  111. Arendt T, Henning D, Gray JA, Marchbanks R. Loss of neurons in the rat basal forebrain cholinergic projection system after prolonged intake of ethanol. *Brain Res. Bull.* 1988;21:563-569. PMID:2850095.
  112. Casamenti F, Scali C, Vannucchi MG, Bartolini L, Pepeu G. Long-term ethanol consumption by rats: Effect on acetylcholine release *in vivo*, choline acetyltransferase activity and behavior. *Neuroscience.* 1993;56:465-471. DOI:10.1016/0306-4522(93)90346-H. PMID:8247273.
  113. Cullen KM, Halliday GM. Neurofibrillary tangles in chronic alcoholics. *Neuropathol. Appl. Neurobiol.* 1995;21:312-318. PMID:7494599.
  114. Cullen KM, Halliday GM. Mechanisms of cell death in cholinergic basal forebrain neurons in chronic alcoholics. *Metab Brain Dis.* 1995;10:81-91. PMID: 7596331.
  115. Heinrich CP, Stadler H, Weiser H. The effect of thiamine deficiency on the acetylcoenzyme A and acetylcholine levels in the rat brain. *J. Neurochem.* 1973;21:1273-1281. PMID: 4761708.
  116. Ehrlich D, Pirchl M, Humpel C. Ethanol transiently suppresses choline-acetyltransferase in basal nucleus of Meynert slices. *Brain Res.* 2012;1459:35-42. DOI: 10.1016/j.brainres.2012.04.020. PMID: 22560095.
  117. Drachman DA. Memory and cognitive function in man: Does the cholinergic system have a specific role? *Neurology.* 1977;27:783-790. PMID: 560649.
  118. Hasselmo ME. The role of acetylcholine in learning and memory. *Curr. Opin. Neurobiol.* 2006;16:710-715. DOI:10.1016/j.conb.2006.09.002. PMID:17011181.
  119. Woolf NJ, Butcher LL. Cholinergic systems mediate action from movement to higher consciousness. *Behav. Brain Res.* 2011;221:488-498. DOI:10.1016/j.bbr.2009.12.046. PMID:20060422.
  120. Benarroch EE. Acetylcholine in the cerebral cortex: Effects and clinical implications. *Neurology.* 2010;75:659-665. DOI: 10.1212/WNL.0b013e3181ee267e. PMID: 20713954.
  121. Hasselmo ME, Sarter M. Modes and models of forebrain cholinergic neuromodulation of cognition. *Neuropsychopharmacology.* 2011;36:52-73. DOI: 10.1038/npp.2010.104. PMID:20668433.
  122. Pepeu G, Giovannini MG. The role of the cholinergic system in cognitive processes. In: *The brain cholinergic system in health and disease.* Giacobini E, Pepeu G, Eds. Informa Healthcare, Abingdon. 2006;221-233.
  123. Picciotto MR, Higley MJ, Mineur YS. Acetylcholine as a neuromodulator:

- Cholinergic signaling shapes nervous system function and behavior. *Neuron*. 2012;76:116-129.  
DOI:10.1016/j.neuron.2012.08.036.  
PMID:23040810.
124. DSM IV. American Psychiatric Association, Washington DC; 1994.
125. Giacobini E. Cholinesterase inhibitor therapy stabilizes symptoms of Alzheimer disease. *Alzheimer Dis. Assoc. Disord*. 2000;14(Suppl 1):3-10. PMID: 10850724.
126. Nitsch RM, Slack BE, Wurtman RJ, Growdon JH. Release of Alzheimer amyloid precursor derivatives stimulated by activation of muscarinic acetylcholine receptors. *Science*. 1992;258:304-307.  
DOI:10.1126/science.1411529.  
PMID:1411529.
127. Fisher A, Pittel Z, Haring R, Bar-Ner N, Kliger-Spatz M, Natan N, et al. M1 muscarinic agonists can modulate some of the hallmarks in Alzheimer's disease: Implications in future therapy. *J. Mol. Neurosci*. 2003;20:349-356.  
DOI:10.1385/JMN:20:3:349.  
PMID:14501019.
128. Coskun P, Wyrembak J, Schriener SE, Chen HW, Marciniack C, Laferla F, et al. A mitochondrial etiology of Alzheimer and Parkinson disease. *Biochim. Biophys. Acta*. 2012;1820:553-564.  
DOI:10.1016/j.bbagen.2011.08.008.  
PMID:21871538.

© 2015 Pepeu et al.; This is an Open Access article distributed under the terms of the Creative Commons Attribution License (<http://creativecommons.org/licenses/by/4.0>), which permits unrestricted use, distribution and reproduction in any medium, provided the original work is properly cited.

*Peer-review history:*

*The peer review history for this paper can be accessed here:*  
<http://www.sciencedomain.org/review-history.php?iid=796&id=32&aid=7169>