



Role of Laparoscopic Retroperitoneal Pyelolithotomy in the Management of Large Renal Calculi: A Retrospective Study of 45 Cases in an Indian Rural Tertiary Care Centre

Sanjeev Singla ^{a#}, Bhopesh Kadian ^{a*‡}, Rohit Virmani ^{a^o} and Garima Dwivedi ^{a‡}

^a Department of General Surgery, BPS GMC Khanpur, Sonapat, Haryana, India.

Authors' contributions

This work was carried out in collaboration among all authors. All authors read and approved the final manuscript.

Article Information

Open Peer Review History:

This journal follows the Advanced Open Peer Review policy. Identity of the Reviewers, Editor(s) and additional Reviewers, peer review comments, different versions of the manuscript, comments of the editors, etc are available here: <https://www.sdiarticle5.com/review-history/90488>

Original Research Article

Received 09 June 2022
Accepted 19 August 2022
Published 24 September 2022

ABSTRACT

Objective: We evaluated the role of laparoscopic retroperitoneal pyelolithotomy in the management of large renal calculi.

Methods: A retrospective study including 45 cases (male, 27; female, 18) of solitary renal calculi of size more than 2.5cm were evaluated. There were 41 patients with single calculus, 4 patients with a staghorn calculus. Laparoscopic retroperitoneal pyelolithotomy was performed using balloon dissection with minor modifications.

Results: Stone clearance was achieved in all forty-five cases. The mean operative time was 90 min. Postoperative hospital stays averaged 5 days. Patients were ambulatory in 24 hours and returned to work in 7 days on average. The minor complications encountered were peritoneal rent, balloon rupture, and superficial wound infection. The postoperative analgesic requirement was average, the patients required 1 tablet of diclofenac sodium (50 mg of diclofenac) for an average duration of 2 days.

Conclusions: Laparoscopic retroperitoneal pyelolithotomy is a suitable minimally invasive method for the treatment of patients with staghorn and large renal calculi in centers without robotic facilities.

Senior Professor;

‡ Senior Resident;

^o Assistant Professor;

‡ Junior Resident;

*Corresponding author: E-mail: bhopeshkadian@gmail.com;

Keywords: Laparoscopy retroperitoneal pyelolithotomy; renal calculi; minimal invasive surgery.

1. INTRODUCTION

“With the introduction of percutaneous nephrolithotomy (PCNL), extracorporeal shock wave lithotripsy (ESWL), and other procedures, multimodality therapy for kidney stones has evolved over the last two decades from invasive to minimally invasive to non-invasive methods. After Clayman and colleagues” [1] first reported laparoscopic nephrectomy, the notion of stone removal by laparoscopy has evolved, especially since Gaur et al. [2] described retroperitoneal balloon dilatation and retroperitoneoscopy. Open renal surgery to treat renal calculi is reserved for exceptional circumstances; it is required in only 0.47 to 5.4% of patients [3]. Large renal stones are best treated by laparoscopy, which has a high stone-free rate and only requires one session [4]. The importance of retroperitoneoscopic surgery in the removal of non-functioning kidneys and renal tumours has been established [5]. However, the role of Laparoscopic retroperitoneal pyelolithotomy in the treatment of renal stones remains unknown.

“Although indications have not been established, successful laparoscopic retroperitoneal therapy for renal stones has been described” [5-8]. “Indications for laparoscopic retroperitoneal pyelolithotomy are in patients with a large single stone in the renal pelvis, percutaneous failure of renal access, where ESWL and PCNL are not feasible due to lack of equipment and expertise, morbid obesity, and minimally branched staghorn calculus in the renal pelvis” [9,10]. This study aims to assess the effect of laparoscopic retroperitoneal pyelolithotomy in the treatment of renal calculi and to present our preliminary findings.

2. MATERIALS AND METHODS

The retrospective study was conducted at the Department of General Surgery, BPS Government Medical College Khanpur, Sonapat, Haryana, India including cases from January 2015 to December 2021. The ethics committee of the institution approved it. The study included 45 cases of solitary renal calculus that included 4 patients with staghorn calculi. All records of patients aged 17 to 70 years with a stone size greater than 2.5 cm [Table 1]. The exclusion criteria were recurrent stones, stones in calices, multiple stones, pregnant patients, congenital abnormalities of the kidney, previous kidney

surgery and a history of recurrent pyelonephritis. The preoperative evaluation of all patients included the following investigations: X-ray KUB, renal function tests, namely, blood urea and serum creatinine, urine routine and microscopy, urine culture and antibiotic sensitivity, USG KUB, CT urography, and DTPA scan in selected patients. Statistical analysis done by using IBM SPSS 23.0.

Table 1. Pre-operative demographic data of patients

Patient characteristics	Value
Total patients	45
Age in yrs (Mean ± SD)	30.4±10.2
Sex(M:F)	27:18
Stone size in cm(Mean ± SD)	2.8±0.6

2.1 Operative Details

All the patients received routine pre-operative and post-operative antibiotics (Ceftriaxone + sulbactam 1.5gm, Gentamicin 60mg, and Metronidazole 100ml). The patient was then moved to a right or left lateral position, depending on the side of the patient on which the operation was performed. Three ports were made; the first port of 1.5 cm size was at the lateral border of the erector spinae in the umbilicus line. A long haemostatic artery was inserted into the retroperitoneal space to create the space followed by index finger to make sure correct plane by feeling the lower pole of kidney. Then a working space was created retroperitoneally by a balloon (rubber water) filled with 1000-1100 ml of normal saline and kept in place for a minimum of 3 minutes to achieve bloodless space. Two other working ports 5 mm in size, one in the renal angle just below the 12th rib at the lateral border of the sacro-spinalis muscle, and the 3rd was anterior and 1 cm above the anterior superior iliac spine [Fig. 1].

Finally, a Hasson trocar was inserted in the middle of the port of 10 mm size, fixed to the musculature with a silk 1-0 suture and covered with dynaplast to avoid air leakage and subcutaneous emphysema [Fig. 2].

CO₂ insufflation was performed until 12mm Hg tension was reached. The ureter was recognized and the renal pelvis identified; the incision was made with an Endo knife or directly with a scissor. The incision in the renal pelvis will be

made as high as possible and will be linear or curvilinear depending upon the configuration of the stone and the exposure of the renal pelvis. The stone was kept in the retroperitoneal space. The DJ stent was inserted through the 5mm port with the help of the laparoscopic sheath through the 5mm port. We did not insert the DJ before proceeding to surgery. The pelvis was closed

with interrupted intracorporeal suturing with absorbable 4-0 vicryl suture [Fig. 3]. The stone was removed through a 10mm port by using one of the 5mm ports as the camera port. Suction drain(8f) was placed through the lower 5 mm port and removed 24-48 h after foley removal. The ureteral stent was kept for 5-6 weeks and confirmed on KUB X-ray the next day of surgery.

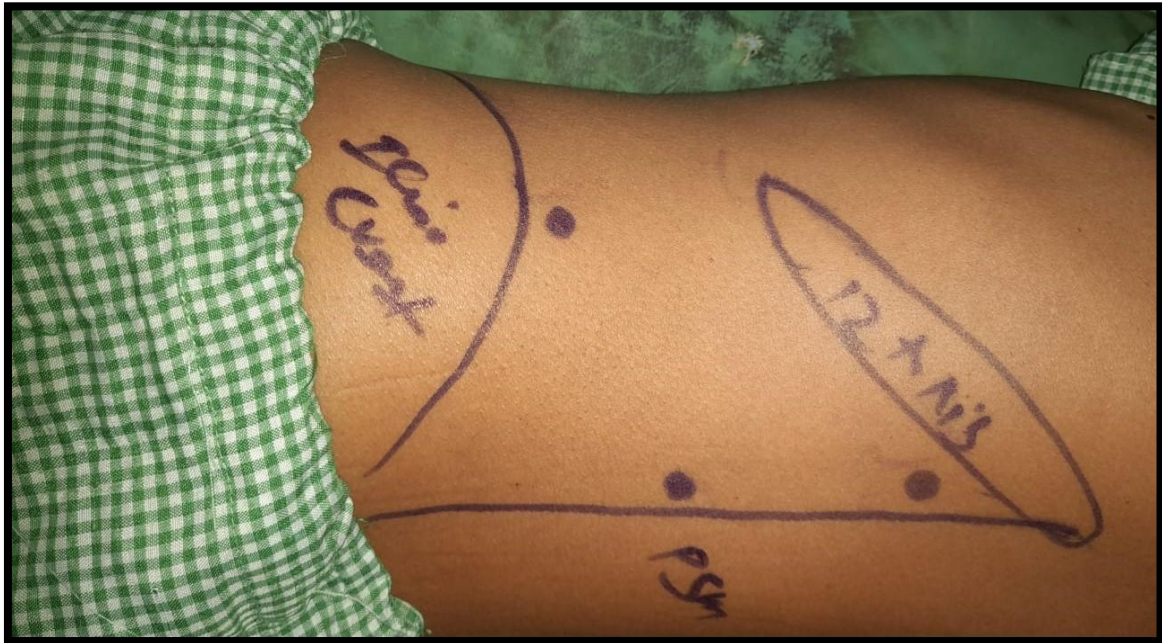


Fig. 1. Pre-operative picture showing the landmark for insertion of the trocars at three ports

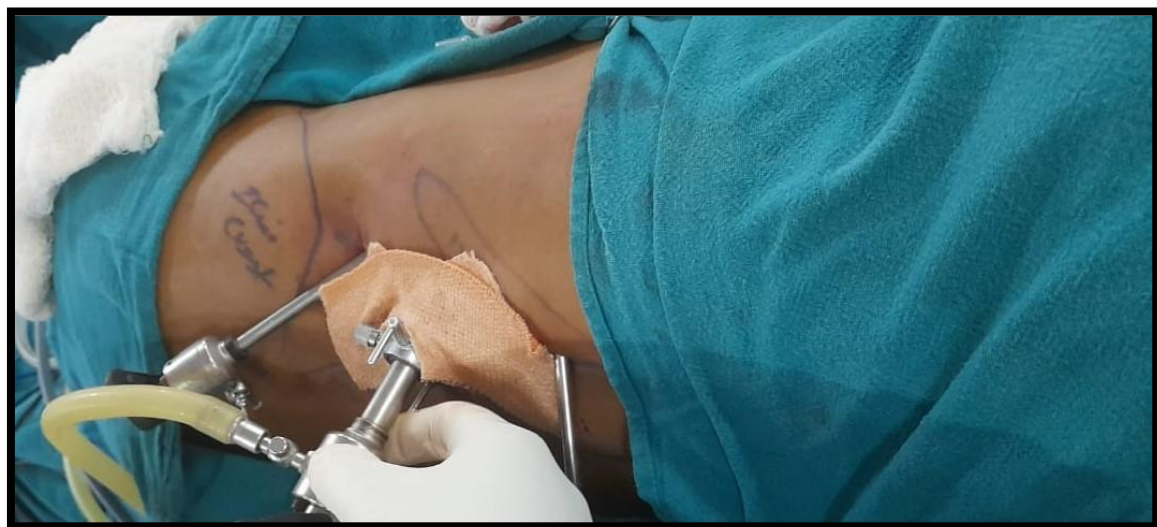

Fig. 2. Use of hasson cannula in 10 mm port and use of dynaplast after suturing to prevent air leakage

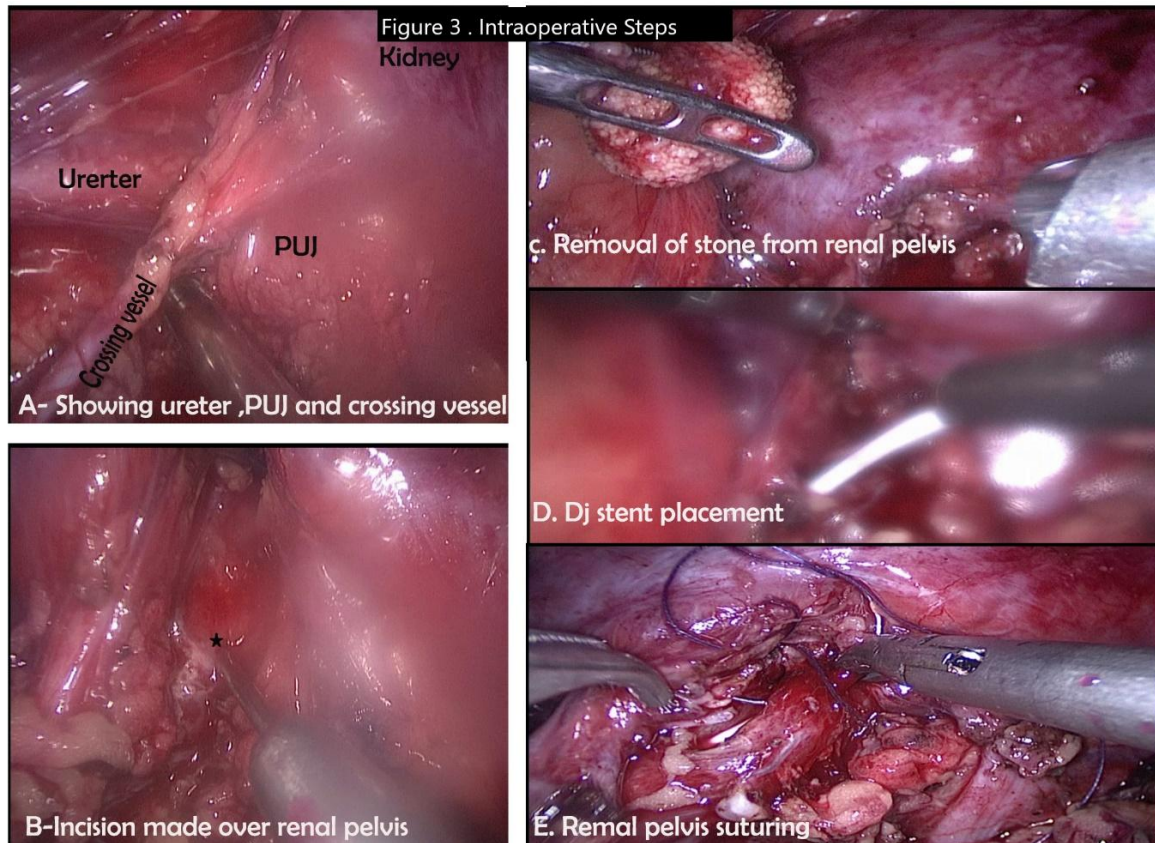


Fig. 3. Intraoperative Steps of Surgery. (A) Showing ureter, PUJ and crossing vessel, (B) Incision over renal pelvis, (C) Removal of stone, (D) DJ stent placement, (E) Intracorporeal suturing of renal pelvis

3. RESULTS

The mean operating time was 90 minutes. For the initial 15 cases, it was an average of 110 minutes, but for later cases it dropped to average 80 minutes. Mean haemoglobin drop was 0.7 ± 0.3 . No blood transfusion was required in any of the patients. The drainage ranged from 600 mL/day to 30 mL/day. Average drainage was 100 mL/day in the first 48 hours. The drain removal ranged from 36 hours to 4 days. The mean time for drain removal was 38.8 ± 9.8 hours. The drain was removed whenever the drainage was less than 10 ml / day. Overall, stone clearance occurred in 45 of the 45 patients (100%) [Table 2].

Post-operative pain was quantified using a visual analogue scale (VAS score) and the total quantities of analgesic and diclofenac sodium used in the postoperative period. For postoperative day 0, intramuscular diclofenac was used, which later shifted to oral tablets from

day 1. The postoperative analgesic requirement was average, the patients required 1 tablet of diclofenac sodium (50 mg of diclofenac) for an average duration of 2 days [Table 3]. The postoperative pain was measured using VAS (Visual analogue scales) [Table 3]. The average duration of hospital stay was 4.5 days. The time taken to resume normal activities was 7 days. Laparoscopic pyelolithotomy is cosmetically superior to open pyelolithotomy. The average scar size was 3 cm (range 3-3.5cm).

One patient (2.2%) had peritoneal rent while performing retroperitoneal balloon dissection. Two patients had balloon rupture while the retroperitoneal space was being created. Two conversions (4.4%) to open pyelolithotomy were necessary due to migration of the stone into the calyx. One patient (2.2%) developed postoperative 12mm port site wound infection which later closed by secondary suturing [Table 4].

Table 2. Peri and post operative data in patients

Parameter	Value (Mean±SD)
Mean operative time (min)	90±30
Average drainage (mL/day)	100±50
Drain removal (hrs)	38.8±9.8
Stone clearance (%)	100
Post- operative hospital stay (days)	4.5±2.2
Post- operative analgesia (days)	2±1.2
Blood Transfusion (%)	0
Average scar size (cm)	3

Table 3. Post-operative VAS score and analgesia

	VAS score	Dose of analgesia (mg)
Day 1	4.1±1.4	100±28.4
Day 2	2.2±0.6	50±15.3
Day 3	1.2±0.2	10±5.6

Table 4. Rate of complications

Complication	Value (%)
Peritoneal Rent	1(2.2%)
Balloon Rupture	2(4.4%)
Conversion to Open	2(4.4%)
Subcutaneous Emphysema	0(0.0%)
Superficial Wound infection	1(2.2%)

4. DISCUSSION

Renal calculi is the most frequent ailment globally, and urologists debate its therapy extensively. Laparoscopic Pyelolithotomy (LP) is a procedure that can be used when SWL and PCNL are not an option, as well as when there are renal abnormalities or a single big stone in the renal pelvic calculus [11]. Due to the difficulties in producing the appropriate pneumoretroperitoneum with direct insertion of a needle into the retroperitoneum, the development of retroperitoneoscopic surgery, including laparoscopic retroperitoneal pyelolithotomy, had been slower than that of transperitoneal laparoscopic surgery.

“However, Gaur’s invention of the balloon dissection technique in 1992 brought about a new era in retroperitoneoscopic surgery” [2]. The retroperitoneoscopic technique, in which space is produced with the use of a balloon, is commonly used. It provides complete visibility of the urinary system, is simple to manage, and avoids urine leaks into the peritoneum. The primary disadvantage of the retroperitoneoscopic method is the smaller working area, which makes suturing the urinary system difficult. In our experience, using a balloon to create a retroperitoneal space is effective and bloodless. Suturing the pelvis was not difficult for us, although it was challenging in intrarenal pelvis situations.

According to certain research [12]. “creating the pneumo-retroperitoneum by needle in retroperitoneoscopic surgery with RP is often difficult and slow compared to the transperitoneal technique. In our center, a long curved artery sheath was penetrated to access the retroperitoneum area, and the fat was separated using the balloon without any peritoneal breach. They claimed that hospital stays are shorter and aesthetic outcomes are better with laparoscopic retroperitoneal pyelolithotomy. Even the odds of converting from retroperitoneum laparoscopy to open surgery are minimal, with little complications. Our findings also revealed that laparoscopic retroperitoneal pyelolithotomy is a good option”.

As shown below, previous Laparoscopic retroperitoneal pyelolithotomy studies have been compared with our findings [Table 5]. Initial studies of Gaur et al. [2], Micali et al. [13], Hemal et al. [7] had a small sample size ranging from 7 to 11 with a clearance rate of 62%,90% and 71% respectively. As these three studies done in initial days of retroperitoneoscopic, the mean operative time range from 108.2 mins to 249mins. Over the years different studies showed a decrease in mean operative time, a high stone clearance rate, a decrease in open conversion and shorter hospital stays. Our findings were comparable to these studies.

Our study also revealed that our patients were stone-free, had no parenchymal or blood loss, and recovered quickly. Although the renal pelvis may be accessible directly with the retroperitoneal technique, this eliminates considerable dissection, urine and blood leakage into the peritoneal space, and allows for faster

Table 5. Comparison between different studies

Study	No. of patients	Clearance	Mean operative time (mins)	Conversion Rate	Mean postop hospital stay	Blood loss(ml)	Removal of drain (hrs)
Gaur et al. [2] [1992]	8	5(62%)	120	2(25%)	-	15	7-15days
Micali et al. [13]	11	10(90%)	249	2(18.2%)	4.5	132.9	-
Hemal et al. [7]	7	5(71%)	108.2	2(28%)	4	127.2	-
Chander et al. [8]	56	54(96.4%)	81	2(3.5%)	4.3	27	48hrs- 7days
Al- Hunayan et al. [14]	21	19(90.5%)	93.2	2(9.5%)	3.8	-	45.6±33
Tefekli et al. [15]	26	26(100%)	138.4	1(3.8%)	3.9	1±0.6 Hb drop	-
Sheng et al. [16]	89	87(98%)	90.87	0(0%)	4.5	0.9±0.5 Hb drop	-
Singh et al. [17]	25	23(92%)	90	2(8.0%)	5	25	48hrs-7days
Singal et al. [18].	850	-	84.2	-	2.5	51.7	24.7±8.9
Present Study	45	45(100%)	90	2(4.4%)	4.5	0.7±0.3 Hb drop	38.8±9.8

recovery. According to Eterovic et al. [19], “although open pyelolithotomy improves renal function from day one, ESWL initially reduces it and then, at best, gets it back to pretreatment levels over a period of months. These findings indicate that retroperitoneal laparoscopic pyelolithotomy, which is comparable to open pyelolithotomy in terms of procedure, not only preserves nephrons but also revives nephrons”.

“Renal stones greater than 3 cm generally necessitate numerous ESWL or PCNL treatments, or both, as well as adjuvant endoscopic procedures and ionising radiation exposure in PCNL. Some patients may not be fully stone-free even after therapy. Laparoscopic retroperitoneal pyelolithotomy has the ability to completely remove stones from these individuals in a single sitting, while also being noninvasive to the kidneys. When the stone is big or several calculi are present, the difference between laparoscopic retroperitoneal pyelolithotomy and other techniques is more obvious. For staghorn calculi, retroperitoneoscopic pyelolithotomy can be used, and the patient is stone-free in one sitting, compared to percutaneous nephrolithotomy, which requires many sittings and exposes the patient to ionising radiation” [20]. “Open surgery is rapidly being substituted by laparoscopy, and a rising number of publications have emerged in recent years demonstrating the usefulness of LP, particularly in patients who require concurrent pyeloplasty” [21], such as those with stones in an ectopic [22] or horse-shoe kidney [23].

Nambirajan et al. [24] compared “transperitoneal and retroperitoneal laparoscopic nephrectomy in a prospective randomised trial. They came to the conclusion that there was no difference between the two treatments in terms of patient morbidity or procedural complexity. However, we discovered that direct access to the renal pelvis of the retroperitoneal approach allows us to better mimic open surgical procedures without the need for bowel manipulation, resulting in a lower risk of postoperative ileus and bowel damage. Blood that is lost during retroperitoneal operations does not come into touch with the intestine, and any urine leakage is kept inside the retroperitoneum”. Blood and pee have been shown to irritate the gut and lengthen the time it takes to regain complete bowel function. Because of the scarcity of area and the lack of landmarks, Laparoscopic retroperitoneal pyelolithotomy has a high learning curve, making it difficult for novices to learn. The psoas muscle,

Gerota's fascia, and the diaphragm are anatomical landmarks that aid operator orientation in the retroperitoneum and enhance clinical outcomes. Early in the process, meticulous and appropriate balloon dissection of the retroperitoneal area may assist the identification of these anatomical features and reduce operating time. So, surgeon experience reduces complications, the duration of the procedure, and may lead to improved success rates.

In this series, the only minor technical complications were peritoneal rent and balloon rupture. Peritoneal rent happened in one patient due to extensive dissection in the retroperitoneal space. As reported by other series, complications like subcutaneous emphysema did not occur in our patient due to the use of Hasson's cannula and use of dynaplast to prevent air leak.

Our study has the following limitations. First this is a retrospective study with limited patient load as due to a budding tertiary rural institute. Secondly, only patients with a single stone located in the extrarenal pelvis were included in the study. As our institute is still in the development mode, further experience and improved technical expertise will help in a large sample size study with further improvement in results in the coming years.

5. CONCLUSION

Despite the fact that laparoscopic surgery has become the standard of care for many urological illnesses, the role of open and laparoscopic surgery in the treatment of urinary stone disease remains restricted due to developments in endourological procedures. However, Laparoscopic retroperitoneal pyelolithotomy is a suitable minimally invasive method for the treatment of renal calculi in individuals with staghorn and large renal calculi in hospitals without robotic facilities.

CONSENT

It is not applicable.

ETHICAL APPROVAL

BPS Government Medical College Khanpur, Sonapat, Haryana, India given the written ethical approval and it has been collected and preserved by the author(s).

COMPETING INTERESTS

Authors have declared that no competing interests exist.

REFERENCES

1. Clayman RV, Kavoussi LR, Soper NJ, et al. Laparoscopic nephrectomy: Initial case report. *J Urol*. 1991;146:278–282.
2. Gaur DD, Agarwal DK, Purohit KC. Retroperitoneal laparoscopic nephrectomy: Initial case report. *J Urol*. 1993;149:103–105.
3. Honeck P, Wendt-Nordahl G, Krombach P, Bach T, Häcker A, Alken P, Knoll T, Michel MS. Does open stone surgery still play a role in the treatment of urolithiasis? Data of a primary urolithiasis center. *Journal of Endourology*. 2009 Jul 1;23(7):1209-12.
4. Kijvikai K. The role of laparoscopic surgery for renal calculi management. *Therapeutic Advances in Urology*. 2011 Feb;3(1):13-8.
5. Doublet JD, Barreto HS, Degremont AC, Gattegno B, Thibault P. Retroperitoneal nephrectomy: comparison of laparoscopy with open surgery. *World J Surg*. 1996;20:713-6.
6. Rassweiler JJ, Henkel TO, Stoch C, Greschner M, Becker P, Preminger GM, Schulman CC, Frede T, Alken P. Retroperitoneal laparoscopic nephrectomy and other procedures in the upper retroperitoneum using a balloon dissection technique. *European Urology*. 1994; 25:229-36.
7. Hemal AK, Goel A, Kumar M, Gupta NP. Evaluation of laparoscopic retroperitoneal surgery in urinary stone disease. *J Endourol*. 2001;15(7):701-5.
8. Chander J, Suryavanshi M, Lal P, Singh L, Ramteke VK. Retroperitoneal pyelolithotomy for management of renal calculi. *SLS*. 2005;9(1):97-101.
9. Nouralizadeh A, Simforoosh N, Soltani MH, Sarhangnejad R, Ardestanizadeh A, Shabaninia S, Ziaee SA. Laparoscopic transperitoneal pyelolithotomy for management of staghorn renal calculi. *Journal of Laparoendoscopic & Advanced Surgical Techniques*. 2012 Jan 1;22(1):61-5.
10. Al-Hunayan A, Khalil M, Hassabo M, Hanafi A, Abdul-Halim H. Management of solitary renal pelvic stone: laparoscopic retroperitoneal pyelolithotomy versus percutaneous nephrolithotomy. *Journal of Endourology*. 2011 Jun 1;25(6):975-8.
11. Patloo AM, Sarmast AH, Khan MA, Khan MA, Zaz M, Khan MA, et al. Laparoscopic retroperitoneal pyelolithotomy and open pyelolithotomy: a comparative study. *Turkish Journal of Urology*. 2012;38:195–200.
12. Chander J, Suryavanshi M, Lal P, Singh L, Ramteke VK. Retroperitoneal pyelolithotomy for management of renal calculi. *JLS*. 2005;9(1):97–101.
13. Micali S, Moore RG, Averch TD, Adams JB, Kavoussi LR. The role of laparoscopy in the management of renal and ureteric calculi. *J Urol*. 1997;157:463-6.
14. Al- Hunayan A, Abdulhalim H, El- Bakry E, Hassabo M, Kehinde EO. Laparoscopic pyelolithotomy: is the retroperitoneal route a better approach?. *International Journal of Urology*. 2009 Feb;16(2):181-6.
15. Tefekli A, Tepeler A, Akman T, Akçay M, Baykal M, Karadağ MA, Muslumanoğlu AY, de la Rosette J. The comparison of laparoscopic pyelolithotomy and percutaneous nephrolithotomy in the treatment of solitary large renal pelvic stones. *Urological Research*. 2012 Oct;40(5):549-55.
16. Li S, Liu TZ, Wang XH, Zeng XT, Zeng G, Yang ZH, Weng H, Meng Z, Huang JY. Randomized controlled trial comparing retroperitoneal laparoscopic pyelolithotomy versus percutaneous nephrolithotomy for the treatment of large renal pelvic calculi: a pilot study. *Journal of Endourology*. 2014 Aug 1;28(8):946-50.
17. Singh V, Gupta P, Rudramani, Singh SK, Kumar S, Verma S, Srivastava S. Laparoscopic retroperitoneal pyelolithotomy at UP Rural Institute of Medical Sciences and Research: our initial experience of 25 cases. *Int Surg J*. 2016;3:488-91.
18. Singal R, Dhar S. Retroperitoneal laparoscopic pyelolithotomy in renal pelvic stone versus open surgery-a comparative study. *Clujul Medical*. 2018;91(1):85.
19. Eterovic D, Juretic-Kuscic L, Capkun V, Dujie Z. Pyelolithotomy improves while extracorporeal lithotripsy impairs kidney function. *J Urol*. 1999;161:39-44.
20. Gaur DD, Trivedi S, Prabhudesai MR, Gopichand M. Retroperitoneal laparoscopic pyelolithotomy for staghorn calculus. *J Laparoendosc Adv Surg Tech A*. 2002;12(4):299-303.

21. Ramakumar S, Lancini V, Chan DY, Parsons JK, Kavoussi LR, Jarrett TW. Laparoscopic pyeloplasty with concomitant pyelolithotomy. J. Urol. 2002;167:1378–80.
22. Harmon WJ, Kleer E, Segura JW. Laparoscopic pyelolithotomy for calculus removal in a pelvic kidney. J. Urol. 1996; 155:2019–20.
23. Nambirajan T, Jeschke S, Albqami N, Abukora F, Leeb K, Janetschek G. Role of laparoscopy in management of renal stones: Single-center experience and review of literature. J. Endourol. 2005; 19:353–9.
24. Nambirajan T, Jeschke S, Al-Zahrani H, Vrabec G, Leeb K, Janetschek G. Prospective, randomised controlled study: Transperitoneal laparoscopic versus retroperitoneoscopic radical nephrectomy. Urology. 2004;64:919–24.

© 2022 Singla et al.; This is an Open Access article distributed under the terms of the Creative Commons Attribution License (<http://creativecommons.org/licenses/by/4.0>), which permits unrestricted use, distribution, and reproduction in any medium, provided the original work is properly cited.

Peer-review history:

The peer review history for this paper can be accessed here:
<https://www.sdiarticle5.com/review-history/90488>