



Role of Panretinal Photocoagulation in Improvement of Visual Acuity of Patients with Proliferative Diabetic Retinopathy

**Shabeer Ahmed Bhutto^{1*}, Zakaullah Gopang¹, Safder Ali Abbasi¹,
Naeem Akhtar Katpar¹, Muhammad Yusuf Debar¹ and Vijay Nagdev¹**

¹Department of Ophthalmology Chandka Medical College and Hospital, Shaheed Mohtarma Benazir Bhutto Medical University, Larkana, Pakistan.

Authors' contributions

This work was carried out in collaboration among all authors. Authors ZG, SAB and SAA were involved in conception of idea and study design. Authors NAK and VN did data collection and performed bench work. Author SAB performed the statistical analysis. Authors ZG and MYD managed the literature searches. All authors read and approved the final manuscript.

Article Information

DOI: 10.9734/JPRI/2021/v33i33A31788

Editor(s):

(1) Dr. Mohamed Salem Nasr Allah, Weill Cornell Medical College, Qatar.

Reviewers:

(1) Lakshmi Kuniyal, Aarogyam Health Clinic, India.

(2) Andi Arus Victor, Universitas Indonesia, Indonesia.

Complete Peer review History: <http://www.sdiarticle4.com/review-history/70094>

Original Research Article

Received 18 April 2021

Accepted 23 June 2021

Published 26 June 2021

ABSTRACT

Objective: To determine the improvement of visual acuity in patients having proliferative diabetic retinopathy undergoing panretinal photocoagulation therapy.

Study design: This is a descriptive case series study.

Setting: Study carried out at Ophthalmology Department, Shaheed Mohtarma Benazir Bhutto Medical University Larkana, from 01-10-2019 to 31-03-2020 (06 months).

Materials and methods: We selected patient with proliferative diabetic retinopathy from the retina clinic after taking a careful history and clinical examination including visual acuity anterior and posterior segment examination and then patient selected for panretinal coagulation with the help of frequency-doubled Nd: YAG laser in three or four sittings.

Results: The total of 158 eyes of 110 patients with proliferative diabetic retinopathy were included in this study out of which improvement of visual acuity was found in 38 (24%) eyes and 120 (76%)

*Corresponding author: E-mail: shabeerahmadbhutto@gmail.com;

eyes have no improvement or same vision.

Conclusion: Proliferative Diabetic Retinopathy (PDR) can successfully be treated with panretinal coagulation with the help of frequency doubled Nd: YAG laser therapy.

Keywords: Visual acuity; panretinal photocoagulation; doubled Nd; YAG; photocoagulation.

1. INTRODUCTION

Patients with diabetes mellitus (DM) irrespective of developed or undeveloped countries are becoming victims of irreversible visual impairment 25 times higher than non-diabetics [1,2]. Pakistan's Diabetic retinopathy Prevalence has been around 25%. In which non-proliferative diabetic retinopathy accounts for 15%, while 4% is macular edema and 6% is proliferative diabetic retinopathy [3,4]. From the past 30 years the rising efforts on the advancement of certain existing techniques, development of new ones such as early surgical interventions, laser photocoagulation (LP), intravitreal injections of steroids and availability of specialist care to the patients has led to the early screening, diagnosis, and its accuracy more effective. Meyer-Schwickerath also reported usage of LP as an effective treatment for advanced RPD [5]. As per the thermal mechanism of action, the retinal pigment epithelium absorbs laser light by the melanin pigment cells, causing the coagulation of retinal photoreceptors and RPE. As they form a result laser burns in outer retina because of its reduced consumption of oxygen, which ultimately leads to diffusion of oxygen into the inner retina from the choroid through the windows created by thinning effect of laser therapy to the outer retina [6]. The krypton laser photocoagulation and xenon arc therapy led to remarkable complications related to the vision of the patients by fabricating the full-thickness burns to the retina [7,8]. The reduction in progression of RPD, complete blindness by single-spot pan retinal photocoagulation (PRP) was reported by DRS (Diabetic Retinopathy Study) [9]. They proposed the visible endpoint burns to retina in about 2000 by early Treatment Diabetic Retinopathy Study (ETDRS) suggesting Pan retinal photocoagulation the gold standard for PDR. Now by the conventional photocoagulation hypertrophy of RPE, loss of photoreceptors, damage to the inner retina and even the nerve fibers leading to peripheral/central loss of field of vision because of expansion of laser scars at the rate of (16.5%)/annum with continuous increment by 4 years post pan retinal photocoagulation therapy

is observed. However immediate effects of therapy are inflammation of the retina by high vascular permeability and in the long term as per se the damage to thickness of RNFLT and even ganglion cells can occur [6-10]. Contrary to this the strong association to hemoglobin and melanin/least absorption of xanthophylls with an added advantage of a long operating lifetime and least scattering ability makes frequency-doubled 532nm a superior option of choice [5,10,11]. We studied prospectively the changes in RNFLT via Spectral-domain (SD) type optic coherence tomography (OCT) which depicts signal-to-noise ratio and allows rapid signal assessment, maximum repetition and dependability for measuring RNFLT and it showed that the panretinal photocoagulation therapy produces thinner RNFL in diabetics than non-diabetic retina [12,13]. An improved standard/baseline visual acuity can be achieved with panretinal photocoagulation therapy.

2. MATERIALS AND METHODS

An informed consent was taken after properly explaining the procedure of study and getting approval of ethical committee. This was a case series study with probability consecutive sampling carried out at Retina Clinic, Department of Ophthalmology, Chandka Medical College Hospital at Shaheed Mohtarma Benazir Bhutto Medical University Larkana were included in this study. Recently diagnosed patients of PDR were included in study. Patients having visually significant cataract, patients with history of uncontrolled diabetes (HbA1C > 7.0%), uncontrolled hypertension (>140/90) or previous treatment of diabetic retinopathy (intravitreal anti VEGF/laser photocoagulation), taut posterior hyaloid membrane, advanced diabetic eye disease (Pre-retinal / vitreous haemorrhage or tractional retinal detachment) and cystoid macular edema (on OCT) were also excluded from the study. Complete ocular examination was performed that includes visual acuity both distance and near with and without glasses, colour vision, pupillary reaction, slit lamp examination and application tonometry for intraocular pressure. The patient's pupil was fully

dilated with tropicamide 1% and phenylephrine 10% eye drops for fundus examination with indirect ophthalmoscope 20D lens and 90D lens on slit lamp biomicroscope. Colour fundus photography were taken in all cases to record clinically evident changes and Fundus Fluorescein Angiography was performed, to reach the diagnosis of the proliferative diabetic retinopathy and patients was advised panretinal photocoagulation with the help of frequency doubled Nd:YAG in three or four sittings. Panretinal photocoagulation was performed in patients with fully dilated pupil under topical anaesthesia with proparacain 5mg drops. The following parameters setting for laser photocoagulation was observed such as, the spot size (200-500µm) laser power (300-500 mw) pulse duration (0.05-0.1 second) and then by using panfundoscopic PRP lens for focusing the laser onto fundus. All collected information were entered into the predesigned proforma. statistical analysis was done through statistical software SPSS 22 Version, Mean ± standard deviation were taken for age, duration of Diabetes Mellitus type II, frequency and percentage were calculate for gender, hypertension and improvement of visual acuity yes/no. Effect modifiers were controlled through specification of age, gender, hypertension, duration of Diabetes Mellitus type II, post stratification apply chi-square test taken P-Value ≤ 0.05 as significant.

3. RESULTS

One Hundred and Fifty Eighteyes of 110 patients with proliferative diabetic retinopathy were included in this study. Mean ± SD of age was 58.62±8.45 with C.I (57.02---60.21) years (Table 1). Out of 110 patients 65 (59.09%) were male and 45(40.90%) were female. While 72 (65.45%) patients were hypertensive and 38(34.54%) patients normal. Mean ± SD of duration of diabetes mellitus type II was 13.26±4.85 with C.I (12.34---14.17) years as shown in Table 1.

Improvement in visual acuity was found in 22 (13.92%) eyes of age between (40-55 years) and 16 (10.12%) eyes of (56-70 years) of age and P value found to be highly significant i.e. (0.001). Gender improvement in visual acuity was found in 23 (14.55%) eyes of males and 15(9.49%) eyes of females and P value found to non-significant i.e. (0.742). Improvement in visual acuity of in hypertension were found in 17 (10.75%) eyes with hypertensive positive and 21(13.29%) eyes with hypertensive negative and P value found to be significant i.e. (0.015). Improvement in visual acuity were found in 35 (22.15%) eyes with duration of type II diabetes mellitus 11-20 years and 3 (1.89%) eyes with duration more than 20 years and P value found to be significant i.e. (0.013) (Table 3). Improvement in visual acuity was found in 38 (24%) eyes out of 158 eyes as shown in Fig. 3.

Table 1. Descriptive statistics n=110

Variable	Mean	±SD	95% Confidence Level
Age (Years)	58.62	8.45	57.02-60.21
Duration of Diabetes (Years)	13.26	4.85	12.34-14.17

Table 2. Demographic Variable n=110

Demographic	Frequency (N)	Percentage (%)
Gender		
• Male	65	59.09%
• Female	45	40.90%
Age (years)		
• 40 to 55 years	78	70.90%
• 56 to 70 years	32	29.09%
Hypertension		
• Yes	72	65.45%
• No	38	34.54%
Eye Involved		
• Unilateral eye	62	56.36%
• Bilateral eyes	48	43.63%

Table 3. Efficacy of panretinal photocoagulation according different variable n=158(EYES)

Variable	Improvement of visual acuity		P-Value
	Yes	No	
Age Group(Years)			
• 40 to 55	22(13.92%)	35	0.001
• 56 to70	16(10.12%)	85	
Gender			
• Male	23(14.55%)	69	0.742
• Female	15(9.49%)	51	
HYPERTENSION (years)			
• Positive	17(10.75%)	29	0.0001
• Negative	21(13.29%)	91	
DIABETES MELLITUS (years)			
• 11-20	35(22.15%)	89	0.013
• >20	3(1.89%)	31	

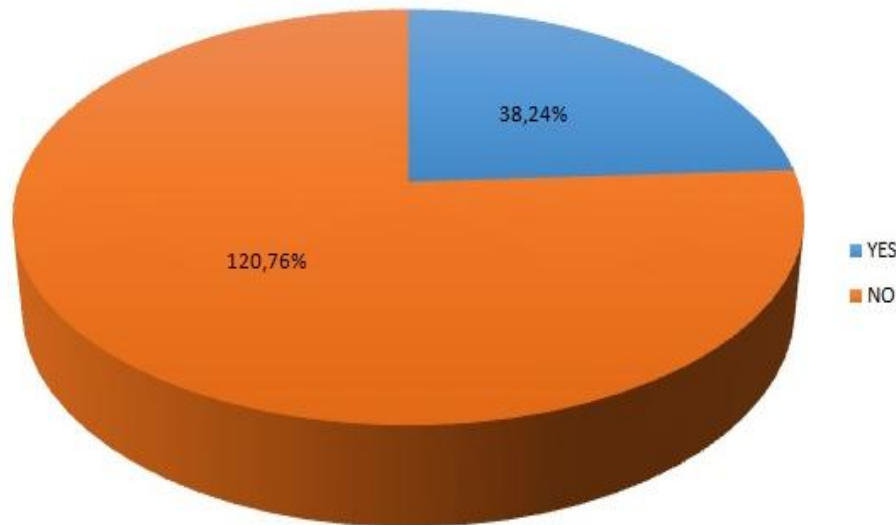


Fig. 1. Improvement of visual acuity n=158

4. DISCUSSION

The assessment of visual acuity improvement after PRP with frequency-doubled Nd:YAG in patients with PDR was targeted in our study. Immediate macular edema and intra-retinal inflammation may cause blindness because of thermal rise and spread in outer retina after undergoing Laser photocoagulation therapy [14,15]. Some studies at animal models suggest that PRP causes macular edema because of leukocyte-endothelial cell inter-playing association with excessive cytokine release and increased permeability of retinal capillaries, so producing outer retinal cone shaped lesions and sparing the inner retina leaving the outer retina as major site of laser burns [16,17]. Some animal

models manifested the fibrosis in laser burns of retina at longer durations of laser pulse [18]. A temporal nerve fiber thickening was reported by Blankenship GW in a rabbit after LP.[19]. A current multi-sitting PRP protocol practice specified by retinologists of UK was used to study the hypothesis for damage of neuronal axons and their progressive loss with time, so we tested the visual fields of our patients to assess that whether the changes in nerve fiber layers are associated with loss of function. We used 300µm along with standard pulseduration for ensuring the adequate intensity of ETDRS burn as a present practice rather than 500µm used by some centers leading to big laser burns with expansion rate of 16.5% [20-23].

Taking into consideration the non-proliferative. Muqit MM et al reported the increase in nerve fiber layer within the temporal quadrant upto 6 months and no decrement after 6 months of PRP for which he standardized 1600 burns in three sittings [24]. Another retrospective study by Johns KJ et al [25] reported a noteworthy decrease of (2.12µm) in NFL by 6 months after the PRP using 1577 burns but no data was available beyond that time frame of 6 months. Similarly this study of ours verifies that NFL thickens and remains thickened till 10 weeks post treatment. Blankenship reports this NFL thickening beyond 30 days [26]. We were also of the view that the 100-ms burns by thermal diffusion may cause the mid-flow axonal flow interruption due to damage and produce edema of axons. We observed that poor glycemic index of patient leads to prolonged post PRP inflammatory phase at 10 weeks. In the five sittings of treatment we came to know that the decreased visual index of patients with 20 years of diabetes was observed as 41% while those with disease process of less than 20 years was about 20% so the duration of diabetes has significance for late i.e one year outcomes post PRP therapy man. Pre procedure poor visual acuity was an a notable prognostic factor following PRP. The 73.2% patients with 6/9 or more visual acuity at first visit maintained it at five sitting follow-up while the 14.3% with visual acuity of < than 6/9 manifested poor vision post PRP by then. Our study subjects receiving PRP showed gender equality along with a strong association of outcome of PRP to age , duration of diabetes ,usage of insulin ,lipid profile,FBS, proteinuria,HbA1c along with a negative association to the other diabetic complications like neuropathy, hypertension and nephropathy which is similar to the results of WHO Multinational Study of vascular disease in diabetes [27-29]. An association with reduction in visual acuity and PDR was elicited. According to our study there is a strong association of HTN with PDR and outcome of patients undergoing PRP and our results are in coordination with United Kingdom Prospective Diabetes Study (UKPDS) ,Korean and Japanese [30,31] So the timely treatment of clinical or subclinical non proliferative DR or PDR is suggested/ need along with other complication associated to diabetes and other comorbidities as well [32,33]. We support the future advancement researches on laser photocoagulation LP and its combination therapy with newer treatments like anti-vascular endothelial growth factors (anti-VEGFs) for improved outcomes [34].

5. CONCLUSION

It is to be concluded that the proliferative diabetic retinopathy (PDR) can successfully be treated with panretinal coagulation with the help of frequency doubled Nd: YAG laser therapy.

CONSENT AND ETHICAL APPROVAL

An informed consent was taken after properly explaining the procedure of study and getting approval of ethical committee.

COMPETING INTERESTS

Authors have declared that no competing interests exist.

REFERENCES

1. Kovacic Z, Ivanisevic M, Karelavic D. The loss of visual field after proliferative diabetic retinopathy treatment with two different techniques of panretinal photocoagulation, *Acta Med Croatica*. 2007;61(2):149-52.
2. Yau JW, Rogers SL, Kawasaki R, Lamoureux EL, Kowalski JW, Bek T et al. Global prevalence and major risk factors of diabetic retinopathy .Meta-Analysis for Eye disease (Meta-Eye) Study Group. *Diabetes Care*. 2012;35(3):556-64.
3. Lim MC, Tanimoto SA, Furlani BA, Lum B, Pinto LM, Eliason D, et al. Effect of diabetic retinopathy and panretinal photocoagulation on retinal nerve fiber layer and optic nerve appearance. *Archives of Ophthalmology*. 2009;127(7):857-62.
4. Klein R, Knudtson MD, Lee KE, Gangnon R, Klein BE. The Wisconsin epidemiologic study of diabetic retinopathy XIV. Ten years incidence and progression of diabetic retinopathy. *Arch Ophthalmol*. 1994;112:1217-28
5. Mayer Schwickerath G. light coagulation (translated by Drance SM). St Louis: Mosby;1960.
6. Steffamson E. Oxygen and diabetic eye disease. *Graefes Arch Clin Exp Ophthalmol*. 1990;228 (2): 120-3.
7. Ober MD, Hariprasad SM. Retinal lasers: Past, present and future. *Ret Physician*. 2009;6:36-9.
8. OAK SM. Green laser photocoagulator for the treatment of diabetic retinopathy.

- Pramana journal of physics. 2010;75(6):1273-79.
9. Maeshima K, Utsugi-Sutah N, Otani T, Kishi S. Progressive enlargement of scattered photocoagulation scars in diabetic retinopathy. *Retina*. 2004;24:507-11.
 10. Early photocoagulation for diabetic retinopathy. ETDRS Report 9. Early Treatment Diabetic Retinopathy Study Research Group. *Ophthalmology*. 1991;98:766-85.
 11. Rema M, Pradeepa R. Diabetic retinopathy: an Indian perspective, *Indian J Med Res*. 2007;125:297-310.
 12. Lim MC, Tanimoto SA, Furlani BA, Lum B, Pinto LM, Eliason D et al. Effect of diabetic retinopathy and panretinal photocoagulation on retinal nerve fiber layer and optic nerve appearance. *Arch Ophthalmol*. 2009;127(7):857-62.
 13. Rema M, Sujatha P, Pradeepa R. Visual Outcomes of pan-retinal photocoagulation in diabetic retinopathy at one-year follow-up and associated risk factors, *Indian J Ophthalmol*. 2005;53:93-9.
 14. Bessette FM, Nguyen LC. Laser light: its nature and its action on the eye. *CMAJ Canadian Medical Association Journal*. 1989;141:1141-48.
 15. Photocoagulation for diabetic macular edema. Early Treatment Diabetic Retinopathy Study report number 1. Early Treatment Diabetic Retinopathy Study research group. *Arch Ophthalmol* 1985; 103: 1796-806
 16. Laser photocoagulation of subfoveal neovascular lesions of age-related macular degeneration. Updated findings from two clinical trials. Macular Photocoagulation Study Group. *Arch Ophthalmol*. 1993; 111: 1200-9.
 17. Photocoagulation treatment of proliferative diabetic retinopathy Clinical application of Diabetic Retinopathy Study (DRS) findings, DRS Report Number 8. The Diabetic Retinopathy Study Research Group. *Ophthalmology*. 1981;88(7):583-600.
 18. McNamara JA, Tasman W, Vander JF, Brown GC. Diode laser photocoagulation for retinopathy of prematurity. Preliminary results. *Arch Ophthalmol*. 1992; 110: 1714-16
 19. McNamara JA, Tasman W, Brown GC, Federman JL. Laser photocoagulation for stage 3+ retinopathy of prematurity. *Ophthalmology*. 1991; 98: 576-80.
 20. Blumenkranz MS, Yellachich D, Anderson DE, Wiltberger MW, Mordaunt D, Marcellino GR et al. New instrument: semiautomated patterned scanning laser for retinal photocoagulation. *Retina*. 2006; 26:370-375.
 21. Al-Hussainy S, Dodson PM, Gibson JM. Pain response and follow-up of patients undergoing panretinal laser photocoagulation with reduced exposure times. *Eye*. 2008;22(1):96-99.
 22. Kulkarni GR. Laser-tissue interaction studies for medicine. *Bulletin of Material Sciences*. 1988; 11:239-44.
 23. Goh PP, National Eye Database Study G. Status of diabetic retinopathy among diabetics registered to the Diabetic Eye Registry, National Eye Database, 2007. *Medical Journal of Malaysia*. 2008; 63Suppl C:24-28.
 24. Muqit MM, Marcellino GR, Henson DB, Fenerty CH, Stanga PE. Randomized clinical trial to evaluate the effects of Pascal panretinal photocoagulation on macular nerve fiber layer Manchester Pascal Study report 3. *Retina*. 2011;31(8):1699-707.
 25. Johns KJ, Leonard-Martin T, Feman SS. The effect of panretinal photocoagulation on optic nerve cupping. *Ophthalmology*. 1989;96(2):211-6.
 26. Blankenship GW. Red krypton and blue-green argon panretinal laser photocoagulation for proliferative diabetic retinopathy: a laboratory and clinical comparison. *Trans Am Ophthalmol Soc*. 1986;84:967-1003.
 27. McNamara JA, Tasman W, Vander JF, Brown GC. Diode laser photocoagulation for retinopathy of prematurity. Preliminary results. *Arch Ophthalmol*. 1992;110:1714-16.
 28. McNamara JA, Tasman W, Brown GC, Federman JL. Laser photocoagulation for stage 3+ retinopathy of prematurity. *Ophthalmology*. 1991; 98:576-80.
 29. Argon laser photocoagulation for macular edema in branch vein occlusion. The Branch Vein Occlusion Study Group. *Am J Ophthalmol*. 1984;98:271-82.
 30. Schatz H, Madeira D, McDonald HR, Johnson RN. Progressive enlargement of laser scars following grid laser

- photocoagulation for diffuse diabetic macular edema. Arch Ophthalmol. 1991; 109:1549-51.
31. Mainster MA. Wavelength selection in macular photocoagulation. Tissue optics, thermal effects, and laser systems. Ophthalmology. 1986;93:952-58.
32. Kim HY, Cho HK. Peripapillary retinal nerve fiber layer thickness change after panretinal photocoagulation in patients with diabetic retinopathy Korean J Ophthalmol. 2009;23: 23–6.
33. Muqit MM, Wakely L, Stanga PE, Henson DB, Ghanchi FD. Effects of conventional argon panretinal laser photocoagulation on retinal nerve fibre layer and driving visual fields in diabetic retinopathy. Eye. 2010;24:1136–4.
34. Tonello M, Costa RA, Almeida FP, Barbosa JC, Scott IU, Jorge R. Panretinal photocoagulation versus PRP plus intravitreal bevacizumab for high-risk proliferative diabetic retinopathy (IBeHi study). Acta Ophthalmol. 2008;86(4):385–9.

© 2021 Bhutto et al.; This is an Open Access article distributed under the terms of the Creative Commons Attribution License (<http://creativecommons.org/licenses/by/4.0>), which permits unrestricted use, distribution, and reproduction in any medium, provided the original work is properly cited.

Peer-review history:

*The peer review history for this paper can be accessed here:
<http://www.sdiarticle4.com/review-history/70094>*