



Synergistic effect of *Ocimum Sanctum* and *Andrographis Paniculata* against Diabetic Complications

**Lalit Gupta¹, Mandeep Kumar Arora^{1,2*}, Ritu Tomar², Anuj Pathak¹,
Vardan Gupta¹, Anchal Garg¹, Jagannath Sahoo² and Parul Grover¹**

¹KIET School of Pharmacy, Ghaziabad-201206, Uttar Pradesh, India.

²School of Pharmaceutical and Population Health Informatics, DIT University, Dehradun-248009,
Uttarakhand, India.

Authors' contributions

This work was carried out in collaboration among all authors. Authors MKA, RT, AP, JS and PG designed the study, performed the statistical analysis, wrote the protocol and wrote the first draft of the manuscript. Authors LG, VG and AG managed the analyses of the study. Author LG managed the literature searches. All authors read and approved the final manuscript.

Article Information

DOI: 10.9734/JPRI/2021/v33i33A31782

Editor(s):

(1) Dr. Vasudevan Mani, Qassim University Saudi Arabia.

Reviewers:

(1) Ananth Kumar Kammala, The University of Texas Medical Branch, United States.

(2) Marwan S. Al-Nimer, Diyala University, Iraq.

(3) Prashant Vishnu Ajmire, Sant Gadge Baba Amravati University, India.

Complete Peer review History: <http://www.sdiarticle4.com/review-history/69858>

Original Research Article

Received 15 April 2021

Accepted 20 June 2021

Published 25 June 2021

ABSTRACT

The present study explored the effect of *Ocimum sanctum*, *Andrographis paniculata* and their combination for the management of experimental diabetic vascular complications. Diabetes associated dyslipidemia and free radical generation have been connected to the pathogenesis of diabetes-induced vascular complications. *Ocimum sanctum*, *Andrographis paniculata*, possess hypolipidemic and antioxidant property, thus we evaluated their vaso-protective potential. Hydroalcoholic extract of *Ocimum sanctum* (200 mg/kg p.o) and hydroalcoholic extract of *Andrographis paniculata* (400 mg/kg p.o) were noted to possess vascular protective potential in experimental chronic diabetes. Experimental diabetes mellitus was induced by Streptozotocin (55 mg/kg i.p., once) to Wistar rats. The induction of diabetes and its associated vascular complications were assessed biochemically. Diabetes-associated dyslipidemia and tissue oxidative stress were

*Corresponding author: E-mail: mmmarora2@gmail.com;

also assessed. Treatment of combination of *Ocimum sanctum* + *Andrographis paniculata* (300mg/kg p.o) was noted to be more efficient against the diabetes-induced vascular endothelial dysfunction and renal impairment as compared to either treatment with *Ocimum sanctum* (400mg/kg p.o) or *Andrographis paniculata* (200mg/kg p.o) or Lisinopril (1 mg/kg/day p.o.) (a reference agent). To conclude, diabetes associate oxidative stress and dyslipidemia are majorly accountable for the induction of vascular and renal impairment. The combination of *Ocimum sanctum* + *Andrographis paniculata* (300mg/kg p.o) shown the synergistic effect and may have prevented the progression of diabetes-induced vascular endothelial dysfunction and nephropathy by preventing the alteration lipid profile, restoring the serum nitrate/nitrite concentration, and decreasing the renal oxidative stress.

Keywords: *Diabetes; oxidative stress; lipid alteration; vascular endothelial dysfunction; nephropathy; combination of Ocimum sanctum + Andrographis paniculata.*

1. INTRODUCTION

Diabetes mellitus is a group of heterogeneous metabolic disorders that share a phenotype of hyperglycemia. Uncontrolled hyperglycemia leads to vascular complications including vascular endothelial dysfunction, atherosclerosis, and nephropathy. Multiple signaling pathways including polyol, Protein kinase C (PKC) pathway, over-generation of advanced glycation end products, and altered hexosamine pathway are associated with induction and progression of vascular complications [1,2]. Endogenous factors such as Insulin growth factors (IGF), Vascular endothelial growth factor (VEGF), Platelet derived growth factor (PDGF), and activated protein C, playing a vaso-protective role and maintaining homeostasis gets inhibited by uncontrolled hyperglycemia [3]. But, the clinical approaches for the management of diabetes and associated complications based on the explored pathway are still unsatisfactory, as the number of patients with diabetic nephropathy and other vascular complications increases year-by-year. It is well noted that dysregulation of the pathways mediated by hyperglycemia intensify oxidative stress or gets provoked by oxidative stress [4]. Thus, in diabetic patients; oxidative stress plays a central role in mediating the progression of vascular complications. Hyperglycemia induced oxidative stress by increasing the generation of reactive oxygen and nitrogen species mediates activation or dysregulation of the pathways causing altered signaling transduction, abnormal gene expression ultimately resulting in progression of vascular complications associated with diabetes [5]. Diabetes dyslipidemia has also been considered as one of the leading pathogenic factors associated with nephropathy (micro) and cardiomyopathy (macro) vascular complications. The correlation between increased blood glucose (hyperglycemia),

hyperlipidemia, and associate oxidative stress suggest that the synergistic effect of hyperglycemia and hyperlipidemia by a common pathway induces oxidative stress which plays a crucial role in the inducing and progressing vascular complication [5,6]. Thereby, to avoid commencement and progression of diabetes-associated vascular complications; it becomes mandatory to target simultaneously this triad of hyperglycemia, hyperlipidemia and associated oxidative stress. Unfortunately, the treatment of vascular complications associated with diabetes by using conventional or synthetic drugs are sometimes associated with serious side effects and are though reported inadequate [3]. Therefore, the demand for herbal medicines is increasing day by day. Due to the presence of a wide variety of phytochemicals, plants are being explored for medicinal properties so as to develop a potent therapeutic agent, which can be used to treat various human health ailments. Various traditional plants have been explored throughout the world for diabetes and associated complications [7]. Due to the higher safety index, low cost and effectiveness herbal drugs are prescribed widely. Therefore, investigation on the phytoconstituents from the herbal plants has gained more importance. *Ocimum sanctum* L. vernacularly known as Tulsi has been used in Ayurveda for more than a thousand years. Tulsi "Queen of Herbs" being the holiest plant of India is most cherished for its healing properties. Alcoholic or other organic solvent fraction extract of Tulsi has been found reported in diabetes as it stimulates insulin secretion from the perfused pancreas of rats, clonal pancreatic β -cells, and isolated islets cells. For secretion of insulin, the mechanism of action proposed for tulsi stated stimulation of adenylyl cyclase/ cAMP or phosphatidylinositol that directly induces mobilization of intracellular Ca^{+2} [8]. Additionally, free radical scavenging potential of aqueous

extract of tulsi was also reported which helped in protecting the organ damage via diabetes by enhancing anti-oxidant enzymes in liver, cardiac tissue and kidney and suppressing high TBARS levels [9]. Moreover aq. Extract of tulsi leaves also helped in decreasing high lipid profile in the serum of high-fat diet-fed rats [10]. *Kalmegh* in Hindi and *Creast* in English is scientifically known as *Andrographis paniculata* (family: - *Acanthaceae*). The ethanolic extract of *A. paniculata* was reported to recover altered lipid profiles in rats with induced diabetes. In addition, concurrent treatment with ethanolic extract of *A.paniculata* and water prevented nicotine-induced mitochondrial electron transport chain complexes inhibition and the resultant increase in nitric oxide (NO) in different parts of rat's brain [11]. Thus, on the basis of free-radical scavenging and anti-hyper-lipidemic activities of *Ocimum sanctum* and *Andrographis paniculata*, the protocol has been designed to explore the effect of *Ocimum sanctum*, *Andrographis paniculata* and combination of *Ocimum sanctum* and *Andrographis paniculata* in diabetes-induced vascular complication in rats.

2. MATERIALS AND METHODS

2.1 Chemicals

Streptozotocin was procured from Sigma-Aldrich Ltd., St. Louis, USA. 1,1,3,3-tetra methoxypropane and carboxymethyl cellulose were purchased from R. K. Enterprises, Meerut, India.

2.2 Plant Material

The aerial part of *Ocimum sanctum* L (Lamiaceae) and aerial part of *Andrographis paniculata* Wall. Ex Nees. (Acanthaceae) were collected from Local market, New Delhi, India in December, 2015. The plant material was authenticated from NISCAIR vide reference no. NISCAIR/RHMD/Consult/2016/ 2944-137-1 (for *Andrographis paniculata*) and NISCAIR/RHMD/Consult/2016/ 2944-137-2 (for *Ocimum sanctum*).

2.3 Experimental Animals

The designed protocol of present experimentation was approved by IAEC (Proposal No. IAEC/KSOP/E/15/008). The study had been conducted on male and female Wistar rats having an average weight of 200-240 g and the same age group. Standard chow diet with

water *ad libitum* was provided to the animals during the study and before conducting the experimentation rats were properly adapted in the Animal House Facility of the institute and animals were provided with normal cycles of day and night.

2.4 Extraction

The extract was prepared by blending 450g of plant in 70%v/v ethanolic solution (1.4L of ethanol and 400ml of water). The mixture so formed was heated for 5 hours and then filtered followed by evaporation at 40°C till it becomes one-third of the initial volume. In a hot air oven remaining solvent was also evaporated [12]. Ash values, foreign organic matter, extractive value, moisture content and phytochemical screening [13,14] were performed for the prepared extract.

2.5 Grouping and Dosing of Animals

Animals were divided into six groups each group consisting of seven rats. Group I (*Normal Control*), with standard food and water only. Group II (*Diabetic Control*), treated with STZ (55 mg/kg, *i.p.*, single dose) by dissolving in citrate buffer (pH 4.5). Group III (*Ocimum sanctum treated diabetic group*), the normal rats were treated with *Ocimum sanctum* (200 mg/kg *p.o.*) for 49 days. Group IV (*Andrographis paniculata treated diabetic group*), rats after seven days of STZ treatment were treated with *Andrographis paniculata* (400 mg/kg *p.o.*) for 49 days. Group V (*Ocimum sanctum+ Andrographis paniculata treated diabetic group*) rats after 7 days of STZ treatment, were treated with combination of *Ocimum sanctum* & *Andrographis paniculata* (300 mg/kg *p.o.*) for 49 days. Group VI (*Lisinopril treated diabetic group*) rats after seven days of STZ treatment, were treated with Lisinopril (1 mg/kg *p.o.*) for 49 days.

2.6 Induction of Experimental Diabetes

Streptozotocin model was employed to induce experimental diabetes in rats. Rats were provided with a single shot of STZ via *i.p* route (55mg/kg) which was prepared in an ice-cold citrate buffer having pH 4.5. Serum glucose level was checked once in the first seven days of STZ treatment. At last (56 days after treatment of STZ), the blood samples were taken by orbital sinus blood collection technique. Serum was separated and stored in a frozen state till the biochemical analysis was completed. The serum glucose level was measured by using the

commercially available diagnostic kit following the GOD-POD method [15].

2.7 Assessment of Metabolic Parameters

Lipid analysis was done by measuring serum total cholesterol, serum triglyceride and serum high density lipoprotein levels using commercially available diagnostic kits following Cholesterol oxidase peroxidase (CHOD/PAP), glycerol phosphate oxidase (GPO/PAP) and polyethylene glycol precipitation methods respectively [16,17].

2.8 Evaluation of Diabetic Nephropathy

Creatinine in serum, blood urea nitrogen (BUN) and proteinuria levels were the parameters performed to assess diabetes induced nephropathy. Alkaline picrate method, Berthelot method and Pyrogallol red method was performed to estimate serum creatinine level, BUN level and proteinuria level respectively [18-20] and all methods were performed by using commercially available diagnostic kit.

2.9 Assessment of Vascular Dysfunction

Serum nitrite/ nitrate estimation was done by following the principle of reduction from nitrate to nitrite in presence of copper-cadmium alloy. This formed nitrate develops colour with Greiss reagent. 0.35M NaOH was used to pause the reaction of nitrate to nitrite and 120mM zinc sulfate solution was used for deproteination of serum sample. A standard plot of sodium nitrite was also made and following spectral method the concentration of nitrate/ nitrite was assessed by checking absorbance at 545nm [21,22].

2.10 Assessment of Renal Oxidative Stress

Thiobarbituric acid reactive substances (TBARS) and reduced form of glutathione (GSH) in renal tissue homogenate were assessed for renal oxidative stress evaluation. Renal tissue homogenate (10% w/v) was prepared in chilled

1.15%KCl solution. TBARS was done to assess the peroxidation of lipids and a traditional method was followed. The standard plot of 1,1,3,3-tertramethoxypropane was made to estimate TBARS level and levels expressed as nmol/mg of protein following the method described by [23]. Glutathione was assessed by following a spectral method in which absorbance of the reaction mixture was checked at 412 nm and a standard plot was also made for reduced glutathione to find out the concentration in a sample of renal tissue and levels were expressed as nmol/mg of protein following the method described by [24].

2.11 Estimation of Total Protein

Renal tissue protein was assessed following a spectral method in which absorbance of the processed sample was taken at 750 nm. The method was defined as Lowry's method in which bovine serum albumin is used as a reference [25].

2.12 Statistical Analysis

All findings represented as mean \pm SD. The data so obtained was statistically examined using one-way ANOVA, and followed by *post hoc* Tukey's multiple comparison tests using graphpad prism.

3. RESULTS

3.1 Morphological Evaluation of *O. sanctum* and *A. paniculata*

The morphological evaluation of plants is summarized in Table 1.

3.2 Standardization parameters of *O. sanctum* and *A. paniculata*

The results of various standardization parameters are summarized in Table 2.

Table 1. Morphological evaluation

S. No.	Features	Observations	
		<i>O. sanctum</i>	<i>A. paniculata</i>
1.	Colour	Green	Dark green above, gray-green below
2.	Odour	Aromatic	Characteristic
3.	Taste	Slightly pungent	Extremely bitter
4.	Size	0.5-1.5 meters in height, 2-4 cm long	length 2 ~11cm Width 0.5~2.5cm
5.	Shape	Oblong, acute, serrate margin.	Apex acuminate, base cuneate, margin shallow undulate, both surfaces glabrous

3.3 Phytochemical Screening of *O. sanctum* and *A. paniculata*

The results of phytochemical screening are summarized in Table 3.

3.4 Pharmacological Evaluation

Hyperglycemia was attained post 72-hours (serum glucose >180mg/dL) of treatment of STZ. Post seven days of STZ treatment, the rats having blood glucose concentrations higher than 260 mg/dL were chosen and were labeled as diabetic rats. *O. sanctum*, *A. paniculata*, a combination of *O. sanctum* & *A. paniculata* and Lisinopril were directed to diabetic rat's post 7 days to the treatment of STZ and their treatments last for 49 days further. All tests were conducted at the end of 49 days in all normal and diabetic rat groups with or without drug treatments. Mortality rate in diabetic rats was below 10 percent.

3.4.1 Effect of herbal interventions on serum glucose

There was a marked rise in serum glucose levels of diabetic rats in contrast to normal rats. Treatment with either *O. sanctum* or *A. paniculata* partially condensed the glucose level in diabetic rats. However, a combination of both *O. sanctum* & *A. paniculata* significantly reduced the elevated levels of serum glucose in diabetic rats. Treatment with Lisinopril showed insignificant reduction in the glucose level (Table 4).

3.4.2 Effect of herbal interventions on serum lipid profile

The rise in serum concentrations of total cholesterol and triglycerides and subsequent decrease in HDL levels were renowned in diabetic rats as compared to normal ones.

Treatment with *O. sanctum*, *A. paniculata* showed partial prevention of diabetes-induced rise in total cholesterol, triglycerides and subsequent reduction in HDL levels. On the other hand, treatment with a combination of *O. sanctum* & *A. paniculata* significantly reduced the diabetes-induced rise in total cholesterol, triglycerides and subsequent fall in HDL levels. However, treatment with Lisinopril partially barred the diabetes-induced rise in total cholesterol and triglycerides and subsequent fall in HDL levels; but results were only significant in triglycerides level (Table 4).

3.4.3 Effect of herbal interventions on serum creatinine and BUN

There was a marked rise in serum creatinine and BUN levels of diabetic rats in contrast to normal rats. Treatment with either *O. sanctum* or *A. paniculata* partially condensed the diabetes-induced increase in serum creatinine and BUN levels. Moreover, treatment with a combination of both *O. sanctum* & *A. paniculata* significantly lowered the raised levels of serum creatinine and BUN as compared to treatments with either herbal intervention alone or Lisinopril in diabetic animals (Figs. 1 and 2).

3.4.4 Effect of herbal interventions on serum nitrite/nitrate concentration

Serum nitrite/nitrate level was noted to be lessened in diabetic rats in contrast to normal rats. Administration of either *O. sanctum* or *A. paniculata* partially attenuated diabetes-associated decrease in serum nitrite/nitrate level. Treatment with combination of *O. sanctum* & *A. paniculata* markedly restored the decreased levels of nitrite/nitrate in diabetic animals when compared with the treatment of either herbal intervention alone or Lisinopril (Fig. 3).

Table 2. Standardization parameters

S. No.	Parameters	Values Obtained	
		<i>O. sanctum</i>	<i>A. paniculata</i>
1.	Foreign Matter	0.07%	0.3%
2.	Moisture Content	8.45%	9.61%
3.	Extractive Value (in Ethanol)	3.02 %	4.70 %
5.	Extractive Value (in Water)	4.07 %	3.46 %
6.	Extractive Value (in Chloroform)	1.4 %	1.33 %
7.	Extractive Value (in Ethyl Acetate)	2.2 %	0.8 %
8.	Extractive Value (in Petroleum Ether)	0.6 %	0.10 %
9.	Total Ash Value	8.7 %	17.5 %
10.	Ash Value (Water soluble)	3.9 %	10%
11.	Ash Value (Acid insoluble)	0.04 %	6.5%

3.4.5 Effect of herbal interventions on proteinuria

A significant rise in the incidence of proteinuria was seen in diabetic rats in contrast to normal rats. Treatment with either *O. sanctum* or *A. paniculata* partially reduced the prevalence of proteinuria in diabetic rats. Moreover, treatment with a combination of *O. sanctum* & *A. paniculata* markedly reduced the prevalence of proteinuria as compared to treatments with either herbal intervention alone or Lisinopril in diabetic rats (Fig. 4).

3.4.6 Effect of herbal interventions on renal oxidative stress

Diabetic rats post 49 days (56 days after STZ administration) presented a noticeable upsurge in renal TBARS in contrast to normal rats. On another hand, levels of GSH in renal tissue were less in diabetic rats in contrast to rats of the normal group. Administration of either *O. sanctum* or *A. paniculata* partially barred the diabetes-induced rise in renal TBARS and fall in renal GSH levels. Furthermore, treatment with combination of *O. sanctum* & *A. paniculata* markedly moderated the diabetes-induced rise in renal TBARS and fall in renal GSH levels as compared to treatments with either herbal intervention alone or Lisinopril in diabetic rats (Figs. 5 and 6).

4. DISCUSSION

In recent years, many reports are available where attempts are being made to develop new drugs to compensate for diabetes and associated vascular complications from traditional medicines. This study aims to evaluate the pharmacological activity of *O. sanctum* and *A. paniculata*. In the present study, streptozotocin-induced diabetes model was used to investigate the anti-diabetic and renoprotective potential of *O. sanctum*, *A. paniculata* and the combination of *O. sanctum* and *A. paniculata*. As fresh material was collected and various physiochemical parameters were performed such as moisture content and foreign matter which was found as 8.45% and 0.07% for *O. sanctum* and 9.61% and 0.3% for *A. paniculata* respectively (Table 4). The moisture content has a substantial role in the storage of drugs and it diverges extractive value differences, which further hampers the dose of drugs. The total ash of *O. sanctum* and *A. paniculata* was found as 8.7 % and 17.5 % respectively, while acid-insoluble and water-soluble ash were found as 0.04 % and 3.9% for *O. sanctum* and 10% and 6.5% for *A. paniculata*,

respectively. In the case of powdered crude drugs, ash value is one of the important parameters which is assessed for the quality and purity of the drug. Ash usually contains salts of sodium, potassium, calcium and magnesium and total ash imitates about the care taken in collection and preparation of crude drug as organic traces are removed during ash formation. The higher value of acid-insoluble ash reflects two cases; first is that the silicates may be present in crude drug and second that the number of calcium oxalates is high in the drug (Table 4). The basis of results gained during the phytochemical screening of plants confirms the quality and purity of the crude drug. The present studies demonstrate that *O. sanctum*, *A. paniculata* and their combination improved glucose level and lipid profile in rats with diabetes. Treatment with these extracts also reduced the 24-hour excretion of urinary albumin and also improved renal oxidative stress in diabetic rats. Additionally, administration of these extracts prevented the progression of vascular endothelium dysfunction by restoring the reduced levels of serum nitrate/nitrite level in rats with diabetes. Further, treatment with these extracts also poses the progression of diabetic nephropathy by reducing serum BUN and creatinine levels in diabetic rats. Oxidative stress is a key player involved in development diabetes and its associated complications [26]. Levels of free radicals are increased as in the case of diabetes the antioxidant defense system [27] is impaired and diabetes itself poses the production of free radicals [28]. Glucose is reduced to sorbitol as it is side tracked to polyol pathway, in which aldose reductase and NADPH from pentose phosphate pathway is utilized and this utilization of NADPH results in the production of free radicals. Various other mechanisms have also been proposed which contribute to the generation of reactive oxygen-free radicals. Oxidation of glucose is believed as another source of free radicals. Keto aldehydes and superoxide anions are produced due to oxidation of glucose by transition-metal based reaction which primarily forms enediol radical anion first [29,30]. The formed free radicals cause plaque deposition and foam cell production in vessels by directly oxidizing the low-density lipoprotein (LDL), and ox-LDL, this oxidized LDL is not recognized by its receptor and is up-taken by the macrophagic scavenger receptor. Increased renal TBARS and reduced GSH are regarded as indexes for the development of oxidative stress [31]. It is noteworthy that higher ROS concentrations reduce the level of bioactive NO

by inactivating it chemically and forms peroxy nitrates which are harmful. Peroxy nitrates uncouple endothelial NO synthase and convert it into a dysfunctional superoxide-generating enzyme which actively contributes to building oxidative load in blood vessels [32]. Thus, the noticeable induction of vascular injury in diabetic rats may be of the expansion of a high rate of oxidative stress and reduction in nitrite/nitrate level in serum. This contention is strongly reinforced by this study, diabetic rats showed higher levels of oxidative stress and significantly lower level of serum nitrite/nitrate concentrations. Oxidative stress potentiates mRNA expression of TGF- β 1 and fibronectin and results in diabetic glomerular injury [33]. Besides TGF- β 1 and fibronectin oxidative stress also activates several kinases like PKC, MAPKs along with some cytokines and transcription factors that support accrual of extracellular matrix in the diabetic kidney and progresses renal impairment [34]. Structurally varying antioxidants were noted to suppresses hyperglycemia-derived activation of PKC in mesangial cells of rats. Furthermore, antioxidants also pose activation of TGF- β and fibronectin throughout the development of diabetes associated nephropathy [4]. Hydroalcoholic extract *O. Sanctum* has been noted to possess anti-oxidant property as both the extract comprises of natural antioxidants (phenols and flavonoids) which are accountable for the anti-oxidative effect of this plant. Treatment with water and ethanolic extract of *A. paniculata* in nicotine derived inhibition of mitochondrial electron transport chain complexes and the resultant increased nitric oxide (NO) levels in various parts of rat brains was preserved. Moreover, aqueous extract of tulsi had been noted to possess a free radical sifting activity that offers organ protection from diabetes by combating high TBARS levels and potentiates antioxidant enzymes in the liver, kidney and cardiac tissues. Taken together a combination of both the extract showed the different signaling pathways for the inhibition of oxidative stress.

The synergistic potential of the combination of *A. paniculata* and *O. Sanctum* may be attributed to the inhibition of mitochondrial electron chain complexes and free radical scavenging activity. Studies implicate that renal disease may progress due to elevated levels of lipids in circulation [35]. Insulin diminishes hormone-sensitive generation of lipase enzyme which increases the deployment of free fatty acids from fat deposits in the periphery, this enhances serum lipid levels. Furthermore, this alteration in lipid levels associates to stimulate the expression of fibronectin, collagen-IV, MAPKs, TGF- β 1 and NF- κ B and results in fibrosis in interstitial spaces of tubules and glomerulosclerosis. Thus, increased levels of lipids in the serum are concerning factors for development and progression of diabetic nephropathy. Treatment with a combination of *A. paniculata* and *O. Sanctum* of diabetic rats has adequately managed the impaired lipid levels. On this basis, a combination of *A. paniculata* and *O. Sanctum* may condense the vulnerability of excessive lipid peroxidation and can stabilize the membrane lipids, thus combats oxidative load. Rise in creatinine and BUN levels are predisposing markers for the diabetes induced nephropathy. Levels of both the markers are advanced in rats having diabetes-induced nephropathy in contrast to normal ones. Maintenance of these biochemical variations nearer to those in normal control rats by a combination of *A. paniculata* and *O. Sanctum* treatment suggests that combination of *A. paniculata* and *O. Sanctum* has a direct or indirect relation in aiding relief towards diabetic nephropathy or postpones its progression. Furthermore, the extent of proteinuria associates with the development of glomerulosclerosis, fibrosis in interstitial spaces of tubules and renal hemodynamic modifications which have been implicated as potential progressors of proteinuria [36]. Management with a combination of *A. paniculata* and *O. Sanctum* markedly anticipates the extant proteinuria in diabetic rats.

Table 3. Phytochemical Screening evaluation

S. No.	Phytochemicals	Present (+) / Absence (-)	
		<i>O. sanctum</i>	<i>A. paniculata</i>
1.	Carbohydrates	+	+
2.	Proteins and amino acids	+	+
3.	Steroids	+	+
4.	Saponins	+	-
5.	Flavanoids	+	+
6.	Alkaloids	+	+
7.	Quinones	+	-

Table 4. Effect of *Ocimum sanctum*, *Andrographis paniculata*, *Ocimum sanctum* + *Andrographis paniculata* and Lisinopril on blood glucose and lipid profile

Assessments	Normal Control	Diabetic Control	<i>O. sanctum</i> (200 mg/kg) Treated Diabetic Group	<i>A. paniculata</i> (400 mg/kg) Treated Diabetic Group	<i>O. sanctum</i> + <i>A. paniculata</i> (300 mg/kg) Treated Diabetic Group	Lisinopril Treated Diabetic Group
Blood Glucose (mg/dl)	103.28 ±9.73	373.45 ±46.04 ^a	284.22 ±30.65 ^b	289.27 ±29.04 ^b	176.87 ±20.54 ^{b,c,d}	333.41 ±43.03
Triglycerides (mg/dl)	100.96 ±9.21	197.21 ±22.58 ^a	148.61 ±16.49 ^b	139.19 ±14.74 ^b	119.44 ±12.45 ^b	158.51 ±17.16 ^b
HDL (mg/dl)	34.08 ±3.39	24.65 ±2.79 ^a	26.16 ±2.28	27.20 ±3.86	32.56 ±3.49 ^b	30.27 ±3.55
Cholesterol (mg/dl)	60.29 ±6.94	86.06 ±10.84 ^a	73.23 ±7.59	75.08 ±8.67	64.64 ±7.42 ^b	81.52 ±11.60

Values are expressed as mean ± SD. a = p < 0.05 v/s normal control; b = p < 0.05 v/s diabetic control; c = p < 0.05 v/s *Ocimum sanctum* treated diabetic group; d = p < 0.05 v/s *Andrographis paniculata* treated diabetic group

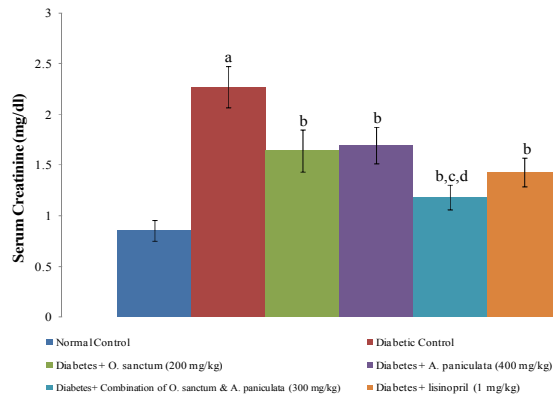


Fig. 1. Effect of *Ocimum sanctum*, *Andrographis paniculata*, *Ocimum sanctum* + *Andrographis paniculata* and Lisinopril on serum creatinine

Values are expressed as mean \pm SD. a = $p < 0.05$ v/s normal control; b = $p < 0.05$ v/s diabetic control; c = $p < 0.05$ v/s *Ocimum sanctum* treated diabetic group; d = $p < 0.05$ v/s *Andrographis paniculata* treated diabetic group

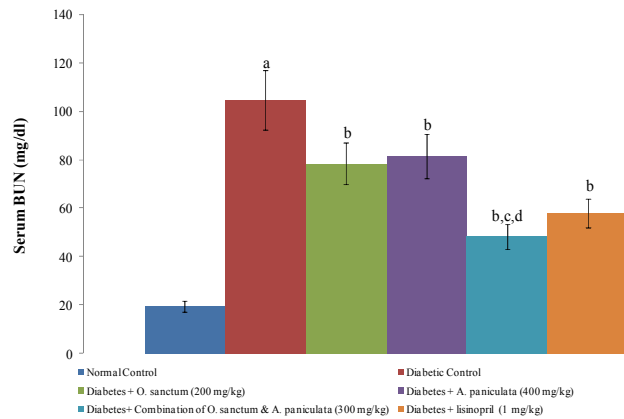


Fig. 2. Effect of *Ocimum sanctum*, *Andrographis paniculata*, *Ocimum sanctum* + *Andrographis paniculata* and Lisinopril on BUN

Values are expressed as mean \pm SD. a = $p < 0.05$ v/s normal control; b = $p < 0.05$ v/s diabetic control; c = $p < 0.05$ v/s *Ocimum sanctum* treated diabetic group; d = $p < 0.05$ v/s *Andrographis paniculata* treated diabetic group

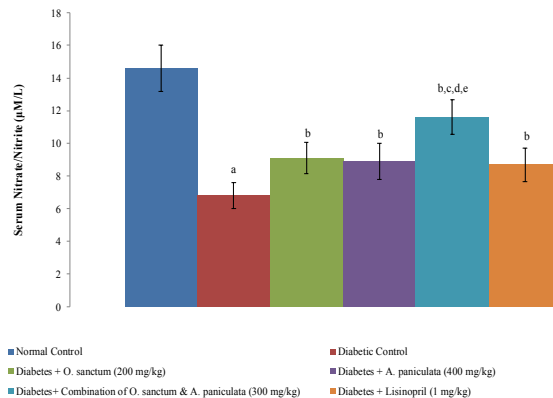


Fig. 3. Effect of *Ocimum sanctum*, *Andrographis paniculata*, *Ocimum sanctum* + *Andrographis paniculata* and Lisinopril on serum nitrate/nitrite concentration

Values are expressed as mean \pm SD. a = $p < 0.05$ v/s normal control; b = $p < 0.05$ v/s diabetic control; c = $p < 0.05$ v/s *Ocimum sanctum* treated diabetic group; d = $p < 0.05$ v/s *Andrographis paniculata* treated diabetic group; e = $p < 0.05$ v/s Lisinopril treated diabetic group

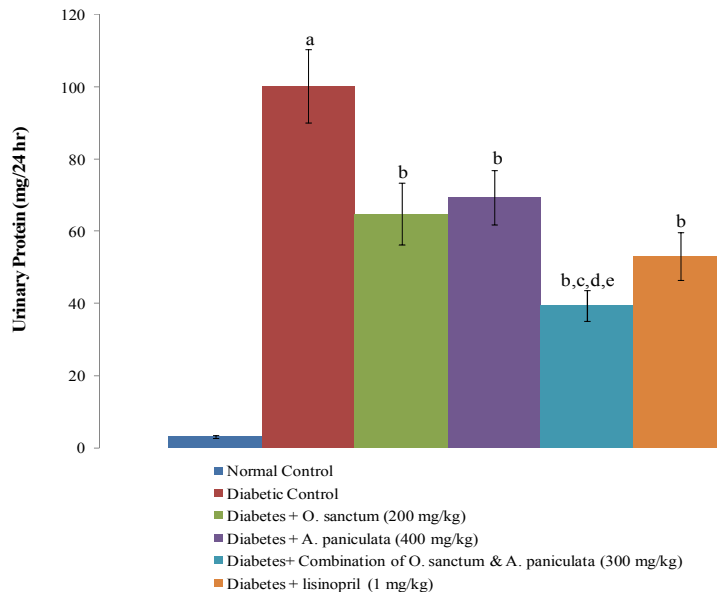


Fig. 4. Effect of *Ocimum sanctum*, *Andrographis paniculata*, *Ocimum sanctum* + *Andrographis paniculata* extract and Lisinopril on protein in urine
 Values are expressed as mean \pm SD. a = $p < 0.05$ v/s normal control; b = $p < 0.05$ v/s diabetic control; c = $p < 0.05$ v/s *Ocimum sanctum* treated diabetic group; d = $p < 0.05$ v/s *Andrographis paniculata* treated diabetic group; e = $p < 0.05$ v/s Lisinopril treated diabetic group

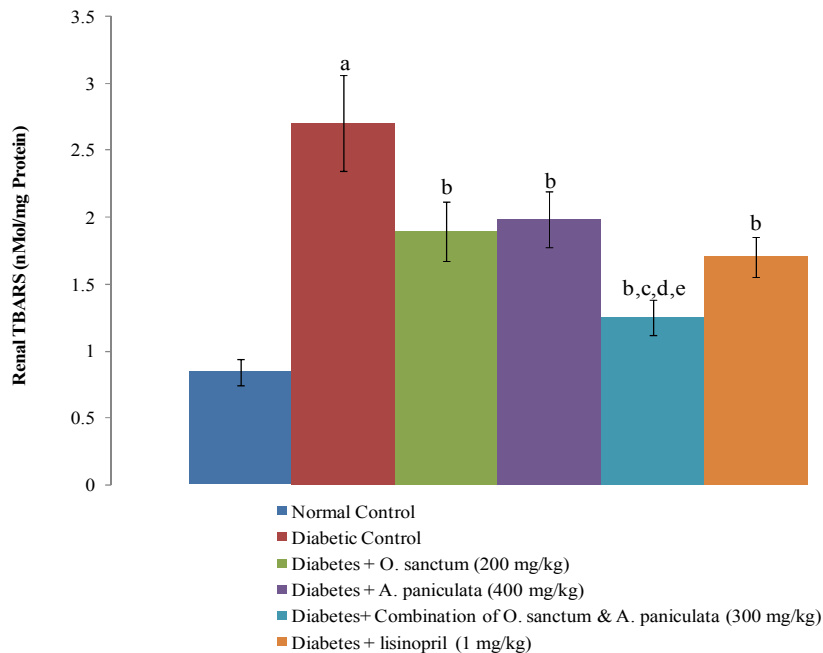


Fig. 5. Effect of *Ocimum sanctum*, *Andrographis paniculata*, *Ocimum sanctum* + *Andrographis paniculata* and Lisinopril on renal TBAR
 Values are expressed as mean \pm SD. a = $p < 0.05$ v/s normal control; b = $p < 0.05$ v/s diabetic control; c = $p < 0.05$ v/s *Ocimum sanctum* treated diabetic group; d = $p < 0.05$ v/s *Andrographis paniculata* treated diabetic group; e = $p < 0.05$ v/s Lisinopril treated diabetic group

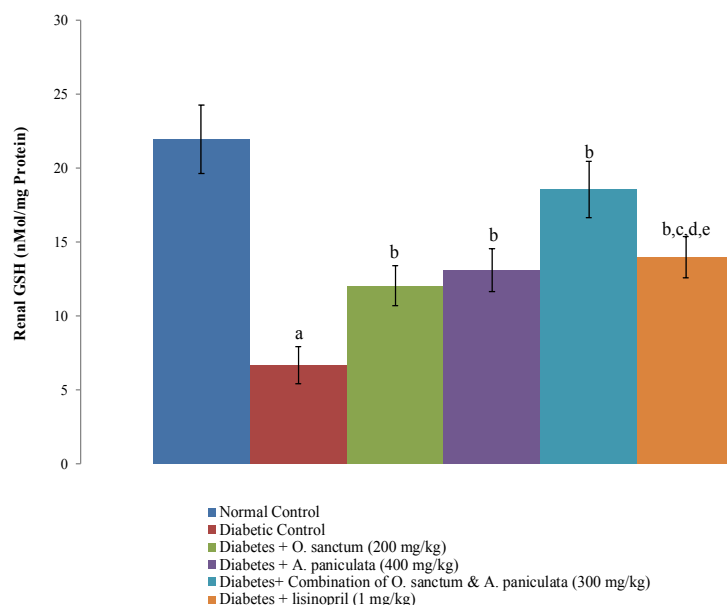


Fig. 6. Effect of *Ocimum sanctum*, *Andrographis paniculata* extract and Lisinopril on renal GSH

Values are expressed as mean \pm SD. a = $p < 0.05$ v/s normal control; b = $p < 0.05$ v/s diabetic control; c = $p < 0.05$ v/s *Ocimum sanctum* treated diabetic group; d = $p < 0.05$ v/s *Andrographis paniculata* treated diabetic group; e = $p < 0.05$ v/s Lisinopril treated diabetic group

5. CONCLUSION

Taken together, it can be concluded that combination of *A. paniculata* and *O. Sanctum* treatments exhibited synergistic effect against diabetic complication by alleviating oxidative stress and by restoration of Nitric oxide. In addition, hypocholesterolemia and hypotriglyceridaemic account to anticipate the development of diabetes associated vascular endothelial dysfunction and nephropathy.

DISCLAIMER

The products used for this research are commonly and predominantly use products in our area of research and country. There is absolutely no conflict of interest between the authors and producers of the products because we do not intend to use these products as an avenue for any litigation but for the advancement of knowledge. Also, the research was not funded by the producing company rather it was funded by personal efforts of the authors.

CONSENT

It is not applicable.

ETHICAL APPROVAL

As per CPCSEA guidelines, the designed protocol of present experimentation was approved by IAEC (Proposal No. IAEC/KSOP/E/15/008).

COMPETING INTERESTS

Authors have declared that no competing interests exist.

REFERENCES

- Arora MK, Singh UK. Molecular mechanisms in the pathogenesis of diabetic nephropathy: an update. *Vascul Pharmacol.* 2013;58(4):259-271.
- Balakumar P, Arora MK, Ganti SS, Reddy J, Singh M. Recent advances in pharmacotherapy for diabetic nephropathy: current perspectives and future directions. *Pharmacol Res.* 2009;60(1):24-32.
- Balakumar P, Arora MK, Reddy J, Anand-Srivastava MB. Pathophysiology of diabetic nephropathy: involvement of multifaceted signalling mechanism. *J Cardiovasc Pharmacol.* 2009;54(2):129-138.

4. Arora MK, Singh UK. Oxidative stress: meeting multiple targets in pathogenesis of diabetic nephropathy. *Curr Drug Targets*. 2014;15(5):531-538.
5. Arora MK, Reddy K, Balakumar P. The low dose combination of fenofibrate and rosiglitazone halts the progression of diabetes-induced experimental nephropathy. *Eur J Pharmacol*. 2010; 2636(1-3):137-144.
6. Arora MK, Sarup Y, Tomar R, Singh M, Kumar P. Amelioration of Diabetes-Induced Diabetic Nephropathy by Aloe vera: Implication of Oxidative Stress and Hyperlipidemia. *J Diet Suppl*. 2019;16(2):227-244.
7. Mestry SN, Dhodi JB, Kumbhar SB, Juvekar AR. Attenuation of diabetic nephropathy in streptozotocin-induced diabetic rats by Punica granatum Linn. leaves extract. *J Tradit Complement Med*. 2016;7(3):273-280.
8. Mondal S, Mirdha BR, Mahapatra SC. The science behind sacredness of Tulsi (*Ocimum sanctum* Linn.). *Indian J Physiol Pharmacol*. 2009;53(4):291-306.
9. Suanarunsawat T, Ayutthaya WD, Thirawarapan S, Pongshompoo S. Anti-oxidative, anti-hyperglycemic and lipid-lowering effects of aqueous extracts of *Ocimum sanctum* L. leaves in diabetic rats. *Food and Nutrition Sciences*, 2014,5,801-881.
10. Suanarunsawat T, Ayutthaya WD, Songsak T, Thirawarapan S, Pongshompoo S. Lipid-lowering and antioxidative activities of aqueous extracts of *Ocimum sanctum* L. leaves in rats fed with a high-cholesterol diet. *Oxid Med Cell Longev*. 2011;2011:962025
11. Hossain, M., Roy, B., Ahmed, K., Chowdhury, A., & Rashid, M. Antidiabetic Activity of *Andrographis paniculata*. *Dhaka Univ. J. Pharm. Sci*. 2007;6(1):15-20.
12. Pham HNT, Nguyen VT, Vuong QV, Bowyer MC, Scarlett CJ. Effect of Extraction Solvents and Drying Methods on the Physicochemical and Antioxidant Properties of *Helicteres hirsuta* Lour. Leaves. *Technologies*. 2015;3(4):285-301.
13. Gunjal AH, Chandola H, Harisha CR, Shukla VJ, Goyal M, Pandya P. Pharmacognostical and Preliminary physicochemical evaluation of Triphaladi granules - A polyherbal Ayurvedic formulation. *Ayu*. 2013;34(3):288-293.
14. Priyadarshi A, Kumari R, Sharma AK, Jaiswal ML. Preliminary pharmacognostic and phytochemical investigation of *Blepharis indica*-T. Anders Seeds. *Anc Sci Life*. 2016;36(2):78-83.
15. Trinder P. Determination of Glucose in Blood Using Glucose Oxidase with an Alternative Oxygen Acceptor. *Annals of Clinical Biochemistry*. 1969;6(1):24-27.
16. Allain CC, Poon LS, Chan CS, Richmond W, Fu PC. Enzymatic determination of total serum cholesterol. *Clin Chem*. 1974;20(4):470-475.
17. Bucolo G, David H. Quantitative determination of serum triglycerides by the use of enzymes. *Clin Chem*. 1973;19(5):476-482.
18. Bonsnes RW, Tausky HH. On Colorimetric Determination of Creatinine by the Jaffe Reaction. *The Journal of Biological Chemistry*. 1945;158: 581-591.
19. Fawcett JK, Scott JE. A rapid and precise method for the determination of urea. *J Clin Pathol*. 1960;13(2):156-159.
20. Watanabe N, Kamei S, Ohkubo A, Yamanaka M, Ohsawa S, Makino K, Tokuda K. Urinary protein as measured with a pyrogallol red-molybdate complex, manually and in a Hitachi 726 automated analyzer. *Clin Chem*. 1986;32(8):1551-1554.
21. Sastry KV, Moudgal RP, Mohan J, Tyagi JS, Rao GS. Spectrophotometric determination of serum nitrite and nitrate by copper-cadmium alloy. *Anal Biochem*. 2002;306(1):79-82.
22. Jindal S, Singh M, Balakumar P. Effect of bis (maltolato) oxovanadium (BMOV) in uric acid and sodium arsenite-induced vascular endothelial dysfunction in rats. *Int J Cardiol*. 2008;128(3):383-391.
23. Ohkawa H, Ohishi N, Yagi K. Assay for lipid peroxides in animal tissues by thiobarbituric acid reaction. *Anal Biochem*. 1979;95(2):351-358.
24. Ellman GL. Tissue sulfhydryl groups. *Arch Biochem Biophys*. 1959;82(1):70-77.
25. Lowry OH, Rosebrough NJ, Farr AL, Randall RJ. Protein measurement with the Folin phenol reagent. *J Biol Chem*. 1951;193(1):265-275.
26. Shinde SN, Dhadke VN, Suryakar AN. Evaluation of Oxidative Stress in Type 2 Diabetes Mellitus and Follow-up Along with Vitamin E Supplementation. *Indian J Clin Biochem*. 2011;26(1):74-77.

27. Matough FA, Budin SB, Hamid ZA, Alwahaibi N, Mohamed J. The role of oxidative stress and antioxidants in diabetic complications. Sultan Qaboos Univ Med J. 2012;12(1):5-18.
28. Tangvarasittichai S. Oxidative stress, insulin resistance, dyslipidemia and type 2 diabetes mellitus. World J Diabetes. 2015;6(3):456-480.
29. Zhang Q, Ames JM, Smith RD, Baynes JW, Metz TO. A perspective on the Maillard reaction and the analysis of protein glycation by mass spectrometry: probing the pathogenesis of chronic disease. J Proteome Res. 2009;8(2):754-769.
30. Asmat U, Abad K, Ismail K. Diabetes mellitus and oxidative stress-A concise review. Saudi Pharm J. 2016;24(5):547-553.
31. Verma S, Reddy K, Balakumar P. The defensive effect of benfotiamine in sodium arsenite-induced experimental vascular endothelial dysfunction. Biol Trace Elem Res. 2010;137(1):96-109.
32. Förstermann U. Nitric oxide and oxidative stress in vascular disease. Pflugers Arch. 2010 May;459(6):923-939.
33. Jeong SI, Kim KJ, Choo YK, Keum KS, Choi BK, Jung KY. Phytolacca americana inhibits the high glucose-induced mesangial proliferation via suppressing extracellular matrix accumulation and TGF-beta production. Phytomedicine. 2004;11(2-3):175-181.
34. Joladarashi D, Salimath PV, Chilkunda ND. Diabetes results in structural alteration of chondroitin sulfate/dermatan sulfate in the rat kidney: effects on the binding to extracellular matrix components. Glycobiology. 2011;21(7):960-972.
35. Abrass CK. Cellular lipid metabolism and the role of lipids in progressive renal disease. Am J Nephrol. 2004;24(1):46-53.
36. MK Arora, UK Singh, R Bansal. Morphological effect of combination of fenofibrate and saxagliptin on kidney of diabetic rats. Int J Pharmacy Pharm Sci 2014;6(4):483-487.

© 2021 Gupta et al.; This is an Open Access article distributed under the terms of the Creative Commons Attribution License (<http://creativecommons.org/licenses/by/4.0>), which permits unrestricted use, distribution, and reproduction in any medium, provided the original work is properly cited.

Peer-review history:

*The peer review history for this paper can be accessed here:
<http://www.sdiarticle4.com/review-history/69858>*