



# **Current Concepts in Bio-minimal Endodontics: A Comprehensive Review on Modern Access Cavity Designs**

**Megha Rao<sup>a†</sup>, B. S. Keshava Prasad<sup>a#</sup>, H. Murali Rao<sup>a‡</sup>  
and Vanamala Narayana<sup>a≡</sup>**

<sup>a</sup> Department of Conservative Dentistry and Endodontics, D.A.P.M. RV Dental College, Bangalore, India.

## **Authors' contributions**

*This work was carried out in collaboration among all authors. All authors read and approved the final manuscript.*

## **Article Information**

DOI: 10.9734/JAMMR/2022/v34i1431384

## **Open Peer Review History:**

This journal follows the Advanced Open Peer Review policy. Identity of the Reviewers, Editor(s) and additional Reviewers, peer review comments, different versions of the manuscript, comments of the editors, etc are available here: <https://www.sdiarticle5.com/review-history/86743>

**Received 18 February 2022**

**Accepted 27 April 2022**

**Published 05 May 2022**

**Review Article**

## **ABSTRACT**

One of the most important steps in endodontic therapy is obtaining an adequate access to the root canal system. This ensures adequate instrumentation, irrigation, visibility, access and disinfection, making endodontic therapy more predictable. However, in the process of gaining a good convenience form, access cavities are being excessively widened, weakening the tooth to masticatory forces and increasing their chance of fracture. Clark and Khademi introduced evidence based new concepts of modern endodontic access designs which primary aims at preservation of tooth structure and increasing fracture resistance of the tooth. Several techniques of modern access designs have been proposed but they all correspond to one fundamental concept, bio-minimalism. This review aims to comprehensively summarize the principles of modern access cavity preparation as well as highlight the various techniques of modern access cavity designs.

**Keywords:** *Bio-minimalism; endolight concept; conservative access designs; ninja access; truss access; guided access; dynamic navigation; image guided access.*

<sup>†</sup>Post Graduate Student;

<sup>#</sup>Head of the Department;

<sup>‡</sup>Professor;

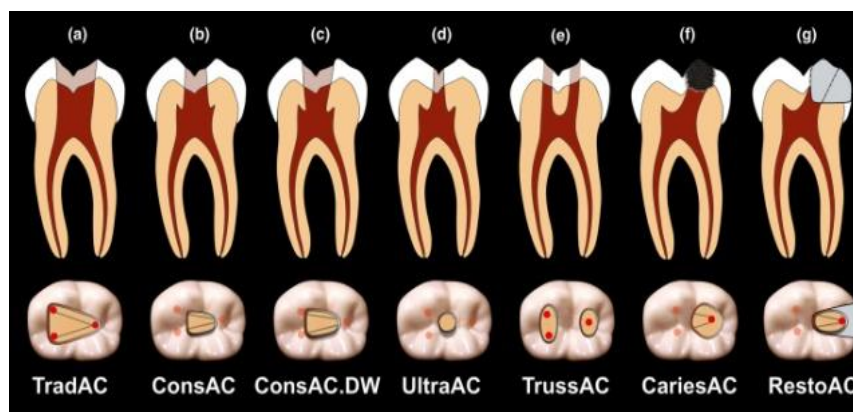
<sup>≡</sup>Reader;

\*Corresponding author: E-mail: dr.rao1995@gmail.com;

## 1. INTRODUCTION

The principles of access cavity preparation proposed by the stalwarts of dentistry like G V Black, Guttman, Weine and Grossman have stood the test of time. However, traditional endodontic access cavity designs have been primarily based on attaining a straight line access and achieving a good “convenience form” for predictable endodontic therapy [1]. These principles are more suited for the operators needs rather than the longevity of the tooth. Teeth are being weakened because of large outline forms, shapes and occult gouging that accompanies the traditional access technique and instrumentation [1,2].

In an attempt to combat the challenges faced in long term success of endodontically treated teeth, David Clark and John A. Khademi brought out a new perspective in modern endodontic therapy [3]. The fundamentals of modern access cavity preparation were now based on more scientifically driven evidence and aim at preservation of tooth structure.



**Fig. 1. Illustration depicting various conservative access cavity designs. 1(a). Traditional access cavity, 1(b). Conservative Access Cavity, 1(c).Conservative Access Cavity with Divergent Walls, 1(d).Ultraconservative Access Cavity, 1(e).Truss Access Cavity, 1(f).Caries Driven Access Cavity, 1(g). Restoration Driven Access Cavity**

(Courtesy: Silva et. al. Current status on minimal access cavity preparations: a critical analysis and a proposal for a universal nomenclature. International Endodontic Journal.)

## 2. MODERN CONCEPTS OF ACCESS CAVITY DESIGN

One of the most common long term complications of endodontically treated teeth is horizontal root fractures [4]. Several studies conducted on fracture resistance of teeth have stated that the remaining dentin thickness post endodontic instrumentation plays a significant role in the distribution of masticatory forces through the tooth during function [2,4]. The junction between the clinical root and clinical crown during function (especially during lateral excursion) bears tremendous shear stresses, in addition to compression on the occluding contacting side and tension on the non-contacting side.

The emergence of modern access cavity design can be primarily attributed to the evolution in

material science, scientific research and instrumentation [5]. This is due to –

- Modern endodontic instrument designs for mechanical debridement(eg: Self adjusting files, XP-Endo Shaper and Finisher)
- Improved chemical disinfection of root canal space through activation of irrigants(preheating, ultrasonic activation and use of LASERS) and active irrigation systems(PIPS, EndoVac)
- Evolution in visualization of canal orifices and canals through magnification(loupes and operating microscopes)
- Improved bonded restorative materials (self-etch adhesives and nano-filled composites)
- Changing concepts in post-endodontic restorations(bonded inlays, onlays, overlays and endocrowns)

- Changes in imaging techniques (from X-ray films to digital imaging and from 2D to 3D imaging)

There are three fundamental concepts of modern access cavity preparation [3]; these are-

1. Preservation of “peri-cervical dentin” (PCD)
2. Obtaining a three dimensional ferrule
3. Formation of “Soffit”

### 3. PERI-CERVICAL DENTIN

This is the portion of the dentin that surrounds the root canal junction between the clinical crown and the root region. Lost tooth structure in the coronal aspect of the tooth can be replaced with an array of materials ranging from composite resins to ceramics. Root canal dentin can also be replaced with various biomimetic materials today. However, the peri-cervical dentin, present at the level of the alveolar crest is irreversible. This is a critical zone, extending 4mm above and 4mm below the crestal bone [3,4] The long term retention of the tooth and resistance to fracture are directly proportionate to the thickness of PCD [6]

The significance of PCD can be attributed to three main factors-

1. Ferrule
2. Fracture resistance
3. Dentinal tubule proximity

#### Ferrule

The ferrule is a band that encircles the residual tooth structure and prevents the tooth from splitting or wearing. It is said that a minimum of 2mm of dentin is key in preventing the formation of fracture lines. Preservation of this is of utmost importance in order to combat the biomechanical responses of the tooth to masticatory forces.

#### Fracture resistance

The preservation of PCD results in the ability of the tooth to withstand both excessive shear and compressive forces during mastication. Inadequate thickness of PCD may result in horizontal fractures of the tooth and crown root separation.

#### Dentinal tubule orifice proximity

The arrangement of dentinal tubules is such that the length of the tubules is least at the cervical region of the tooth. In addition to this, the

thickness of enamel and cementum is significantly lesser. Tooth wear especially after endodontic therapy results in further thinning of the cervical enamel and cementum. The open dentinal tubules serve as a port of entry for microbes and microbial toxins to leach into the root canal space. Preservation of the PCD decreases the ability of these toxins to reach the canal space.

### 4. THREE DIMENSIONAL FERRULE

Understanding the mechanics of how ferrules prevent fractures is key. When a tooth is ferruled, the forces that would be generated in multiple flexure stress planes (in the non-ferruled tooth), are instead distributed over a wider area located at the ferrule margin. Hence, a ferrule can potentially improve the biomechanical stability of a tooth, by ‘shifting’ the interfaces that resist stresses, from weak tooth, core, and post interfaces, to a strong tooth, core, and post interface that is located at the ferrule margin [7,8]. The PCD acts as a ferrule by hugging the remaining tooth structure and redistributing the forces that cause fractures.

### 5. FORMATION OF SOFFIT

Complete deroofting of the pulp chamber roof results in the creation of a occlusally divergent access cavity, excess removal of coronal dentin as well as gouging of lateral walls [9]. Traditional access designs propagated this in order to facilitate complete debridement of the pulp tissue especially the pulp horns. With the advancements in instruments, irrigants and irrigation techniques, the need for direct mechanical access to the pulp horn region is not necessary in order to debride it [6,10,11]. Clark and Khademi have recommended to limit the width of the access cavity preparation without involving the pulp horn region, resulting in the formation of a soffit in that region. A soffit is an architectural term used describe an extension of roof beyond the width of the building. This access cavity design enhances dentin preservation and thereby improves the biomechanical properties of endodontically treated teeth.

Based on the modern principles of access cavity preparation, a number of emerging concepts of access cavity designs have been proposed [5]. A few popular ones are –

- a. Conservative Access Cavity
- b. Ultra conservative access cavity/Ninja access

- c. Truss access cavity/ Orifice directed dentin conservation access cavity
- d. Caries driven access cavity
- e. Restorative driven access cavity design
- f. Cala Lilly enamel preparation
- g. Micro guided endodontic access
- h. Dynamic Navigation guided endodontic access
- i. Image guided endodontic access

## **6. CONSERVATIVE ACCESS CAVITY DESIGN**

The modification of traditional access design from complete deroofing to a preparation that removes less tooth structure. Clark and Khademi have suggested the constricted access is started at the central fossa and then the cavity is extended towards the orifices [3]. The walls between the orifices are not straightened. Rather, the cavity outline follows the location of the orifices on the pulpal floor from centre to the peripheries with occlusally convergent walls. This prevention of diversion of the occlusal cavity results in incomplete deroofing of the roof of the pulp chamber at the pulp horn region resulting in the formation of a “soffit”. Advances in irrigation protocols aid in debridement of the tissue present in the soffit region. The soffit significantly improves fracture resistance of the tooth by increasing the remaining dentin thickness [8,9].

## **7. ULTRA CONSERVATIVE ACCESS /NINJA ACCESS**

This is an extremely conservative design recommended in teeth requiring intentional endodontic therapy and in the absence of caries [5]. The access opening is started from the central fossa with the bur angulated in an oblique projection towards the orifices. High magnification under the microscope is recommended. The use of aided techniques of irrigation like agitation and preheating will ensure adequate debridement of the canals.

## **8. TRUSS ACCESS**

This is an orifice driven access approach. Access to the pulp chamber is gained through narrow holes drilled towards the orifice preserving dentin between the two access cavities [6]. The advantage of this design is that the post endodontic restoration is very conservative and can be managed with restoring the tooth with a resin composite material [9,10].

## **9. CARIES DRIVEN ACCESS**

The carious region is excavated and access is gained through the carious region. The remaining portion of the tooth is left untouched [5,12].

## **10. RESTORATION DRIVEN ACCESS**

This approach is used in teeth with existing restorations and no caries. The access is obtained by removal of the restoration rather than through the existing healthy structure [5].

## **11. CALA LILLY**

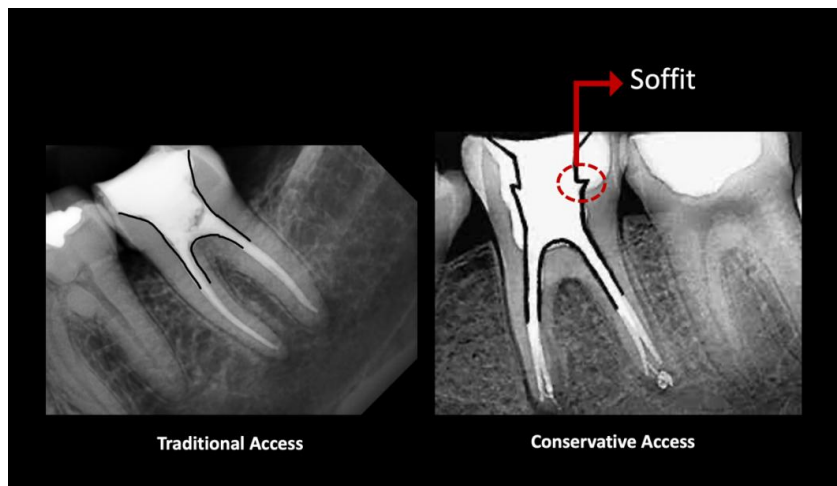
This is a modification of access cavity designs done with the intention of restoring the tooth with a bonded restoration after endodontic therapy. This occlusal modification involves the incorporation of a 45° circumferential enamel bevel, mimicking the shape of a cala lilly flower. The bevel has two roles – to enhance bonding of the final restoration to enamel and to redistribute the vertical masticatory forces across the occlusal plane [3].

## **12. MICRO-GUIDED ENDO ACCESS**

Guided accesses are employed to obtain pin point access to orifices which cannot be detected or accessed through conventional methods. It is particularly useful in location of severely calcified canals. It makes use of a CBCT scan and a special software to fabricate a 3D printed guided stent. The access is gained by passing the bur through a metal sleeve in the guided stent. Once adequate access is gained, the rest of the endodontic therapy is completed without the stent [13,14].

## **13. DYNAMIC NAVIGATION GUIDED ACCESS**

The dynamic navigation was first described by Charles M for dynamic navigation of implants. In the dynamic navigation guided access technique, the depth and orientation of the bur is monitored in real time through an overhead camera that locates the patients jaws and the operators bur in three dimensions. The orientation of the bur is displayed on a viewing monitor. This displays gives feedback to the operator through graphics displayed on a screen, that show the orientation of the bur to the long access of the tooth, the depth of the bur into the tooth and the distance of the pulp chamber from the head of the bur [15].



**Fig. 2. Traditional access with divergent and continuous walls depicting incomplete deroofing of the pulp chamber roof, (b) Conservative access cavity with formation of “soffit” at pulpal horn region**

#### 14. IMAGE GUIDED ACCESS

This is an advanced access opening technique (an alternative method to dynamic navigation) used to perform minimally invasive access cavities by using a computer-controlled device. A CO<sub>2</sub> laser ablation system (9.3µm) is used to access teeth based on spatially calibrated digital image guidance and CBCT scans. Distinct, invariant tooth anatomy is extracted from volumetric data from CBCT scans and then overlaid with digital images of the tooth crown. An interactive augmented reality user interface computer generates the precise location of the internal anatomy and displays it through graphic projections in the digital image. A toolbox of drawing mechanisms is used by the clinician to design the access of choice through the software. In cases in which CBCT scans are unavailable, the clinician can design access using only the digital image, just as a clinician does with his or her eyes and hands currently. The access design is transformed into an algorithm that scans the CO<sub>2</sub> laser over the tooth, cutting the desired shape in a stepwise routine digital image guidance and CBCT scans [15].

#### 15. CONCLUSION

The various access cavity designs all aim at preservation of tooth structure and increasing fracture resistance of endodontically treated teeth [16]. However, there are several challenges

that pose during endodontic treatment [17]. A few of these are—

1. Difficulty in instrumentation during cleaning and shaping, and obturation [18]
2. Inadequate visibility posing difficulty in locating additional canals [18]
3. Decreased flow of irrigants to unexposed regions of the access cavity leading to incomplete debridement [19]
4. Several studies have stated that the fracture resistance of teeth with these minimal access designs are better than those with conventional designs. However, the evidence for an increased fracture resistance is still limited [16,20].
5. The occurrence of iatrogenic errors is still very high while performing these procedures making the outcomes questionable [21,22].

The constant evolution and advancement in endodontic sciences is shifting the axel towards bio-minimal endodontics. A better understanding of the biomechanical responses of teeth to masticatory forces has led to the emergence of these new techniques. It of utmost importance to upgrade the clinical practice with the advances in imaging techniques, visualization and instruments. These will facilitate the difficulties brought about during conservative access preparation. The principles of obtaining access to the pulp chamber should change from establishing a “convenience form” for the operator to a “conservative form” for the tooth.

## CONSENT

It is not applicable.

## ETHICAL APPROVAL

It is not applicable.

## COMPETING INTERESTS

Authors have declared that no competing interests exist.

## REFERENCES

1. Clark D, Khademi J, Herbranson E. The new science of strong endo teeth. *Dentistry today*. 2013;32(4):112-4.
2. Wolters WJ, Duncan HF, Tomson PL, Karim IE, McKenna G, Dorri M, Stangvaltaite L, van der Sluis LW. Minimally invasive endodontics: a new diagnostic system for assessing pulpitis and subsequent treatment needs. *Int Endod J*. 2017;50(9):825-9.
3. Clark D, Khademi J. Modern molar endodontic access and directed dentin conservation. *Dent Clin North Am* 2010;54:249-73.
4. Clark D, Khademi J, Herbranson E. Fracture resistant endodontic and restorative preparations. *Dent Today* 2013;32:118,120-3.
5. Vats S, Mishra P, Nikhil V. Modern access cavity concept: a review. *International Journal of Research and Review*. 2021;8(2):450- 453.
6. Neelakantan P, Khan K, Hei Ng GP, Yip CY, Zhang C, Pan Cheung GS: Does the Orifice-directed Dentin Conservation Access Design Debride Pulp Chamber and Mesial Root Canal Systems of Mandibular Molars Similar to a Traditional Access Design? *J Endod* 2017;44(2):274-279.
7. Kishen A. Mechanisms and risk factors for fracture predilection in endodontically treated teeth. *Endodontic Topics*. 2006; 13:57-83
8. Mamoun JS. On the ferrule effect and the biomechanical stability of teeth restored with cores, posts, and crowns. *Eur J Dent*. 2014;8(2):281- 286. DOI:10.4103/1305-7456.130639.
9. Silva, EJNL, Pinto, KP, Ferreira, CM, Belladonna, FG, De-Deus, G, Dummer, PMH, Versiani, MA. Current status on minimal access cavity preparations: a critical analysis and a proposal for a universal nomenclature. *International Endodontic Journal*.
10. Carvalho MA, Lazari PC, Gresnigt M, Del Bel Cury AA, Magne P Current options concerning the endodontically-treated teeth restoration with the adhesive approach *Braz. Oral Res*. 2018;32(suppl): e74
11. Metzger Z. The self-adjusting file (SAF) system: An evidence-based update. *J Conserv Dent* 2014; 17:401-19.
12. Simon. C, et. at. "Computer Controlled CO<sub>2</sub> Laser Ablation System for Cone-beam Computed Tomography and Digital Image Guided Endodontic Access: A Pilot Study". *J Endod*. 2022; 47(9):1145-1152.
13. Clifford Ruddle. *Tsunami irrigation-EndoActivator by Ruddle*;2008.
14. Preparation Design on the Fracture Strength of Endodontically Treated Teeth: Traditional Versus Conservative Preparation. *J Endod*. 2018;44(5):800-805.
15. Sameer D. Jain, Caroline K. Carrico, IdoBermanis. "3-Dimensional Accuracy of Dynamic Navigation Technology in Locating Calcified Canals". *J Endod*. 2020;46(6):839-845.
16. Tara Jose, et. al. "Endolight Concept: A Minimally Invasive Endodontic future." *IOSR Journal of Dental and Medical Sciences (IOSR-JDMS)*. 2020;19(7):06-17.
17. Gambarini G, Krastl G, Chaniotis A, ElAyouti A, Franco V. Clinical challenges and current trends in access cavity design and working length determination. *Int Endod J*. 2019;52:397-399.
18. Silva, EJNL, Pinto, KP, Ferreira, CM, Belladonna, FG, De-Deus, G, Dummer, PMH, Versiani, MA. Current status on minimal access cavity preparations: a critical analysis and a proposal for a universal nomenclature. *International Endodontic Journal*;2020.
19. Abou-Elnaga MY, Alkhawas MAM, Kim HC, Refai AS. Effect of truss access and artificial truss restoration on the fracture resistance of endodontically treated mandibular first molars. *Journal of Endodontics*. 2020;45:813–7.

20. E. J. N. L. Silva, C. O. Lima, A. F. A. Barbosa, C. M. Augusto, E. M. Souza, R. T. Lopes, G. De-Deus, M. A. Versiani, Preserving dentine in minimally invasive access cavities does not strengthen the fracture resistance of restored mandibular molars, *International Endodontic Journal*, 10.1111/iej.13487, 54, 6, (966-974), (2021).
21. E. J. N. L. Silva, M. A. Versiani, E. M. Souza, G. De-Deus, Minimally invasive access cavities: does size really matter?, *International Endodontic Journal*, 10.1111/iej.13462, (153-155),(2021).
22. Dan Wang, Wei Wang, Yu-Jiao Li, Yi-Rong Wang, Tao Hong, Shi-Zhu Bai, Yu Tian, The effects of endodontic access cavity design on dentine removal and effectiveness of canal instrumentation in maxillary molars, *International Endodontic Journal*, 2021;54(12):2290. 2299.10.1111/iej.13621

© 2022 Rao et al.; This is an Open Access article distributed under the terms of the Creative Commons Attribution License (<http://creativecommons.org/licenses/by/4.0>), which permits unrestricted use, distribution, and reproduction in any medium, provided the original work is properly cited.

*Peer-review history:*

*The peer review history for this paper can be accessed here:*

*<https://www.sdiarticle5.com/review-history/86743>*