



Case Study on Tracheo - Bronchial Stenosis: Conservative vs Bronchoscopic Approach

Mahavir Modi ^a and Kaumudi Devi ^{a*}

^a Department of Pulmonary Medicine, Ruby Hall Clinic, Pune, India.

Authors' contributions

This work was carried out in collaboration between both authors. Both authors read and approved the final manuscript.

Article Information

DOI: 10.9734/JAMMR/2022/v34i231264

Open Peer Review History:

This journal follows the Advanced Open Peer Review policy. Identity of the Reviewers, Editor(s) and additional Reviewers, peer review comments, different versions of the manuscript, comments of the editors, etc are available here: <https://www.sdiarticle5.com/review-history/82456>

Case Study

Received 08 December 2021

Accepted 16 February 2022

Published 23 February 2022

ABSTRACT

Tracheo-bronchial stenosis can occur in infections like tuberculosis, malignancy and post-intubation, trauma to airway. Tracheal and airway stenosis remains a challenging area for pulmonologists and require interventions to cure the patients. The aim of this study is to differentiate treatment approach in the management of variety of tracheo-bronchial stenosis. Patients with stenosis presents with breathlessness, stridor, hoarseness of voice, and are unable to expectorate. In some cases, patient will require emergency intubation and securing the airway before the treatment of stenosis. Intubation may cause mucosal damage and inflammation, granulation tissue formation, cartilage destruction, tracheomalacia and tracheal stenosis. Among these, post intubation tracheal stenosis has worst outcome and require interventions. Early diagnosis of this complication may change the natural history of the disease. If early diagnosis can be established, then bronchoscopy and balloon dilatation, stenting can be done, otherwise patient might have to undergo further resectional lung surgeries or tracheostomy depending on the site of the lesion. Each case of tracheo-bronchial stenosis needs different treatment approach and careful clinical and bronchoscopic evaluation.

Keywords: Argon plasma coagulation; balloon dilatation; post intubation airway stenosis; silicon stenting; tracheal stenosis.

[†]MD, DNB Pulmonary Medicine, Senior Consultant;

[°]Final Year DNB Pulmonary Medicine, Resident;

^{*}Corresponding author: E-mail: kaumudidevi12@gmail.com;

1. INTRODUCTION

Tracheo-bronchial stenosis can occur due to a wide variety of reasons including post intubation, post tuberculosis infection, malignancy, trauma. Patients with tracheobronchial stenosis due to tuberculosis (TSTB) have a variable clinical course and response to treatment including airway intervention. There are no clear guidelines on the best approach to manage such patients. Airway stenosis is a technically challenging pathology to deal with and there are various aetiologies which can lead to the stenosis including post intubation trauma which is the most common reason [1].

Tracheobronchial tuberculosis (TBTB) is reported in approximately 10% to 39% of the patients with pulmonary tuberculosis. Bronchoscopy is the most definite method of diagnosis which provides adequate specimens for microbiological and histopathological diagnosis. Tracheobronchial stenosis is one of the most common long term complications of TBTB resulting in significant morbidity [2]. The management involves conservative approach alone or balloon dilatation, argon plasma coagulation or stenting. The approach can be taken after clinical evaluation of the patient and considering the risk to benefit ratio.

2. CASE PRESENTATION

2.1 Case 1

24 year old male, got admitted in intensive care unit in a peripheral center with encephalopathy and got intubated in view of respiratory distress. Post intubation, there was difficult weaning and patient was tracheostomised. After 6 months, tracheostomy was decannulated and post tracheostomy closure, patient was sent home. After 1 week, patient presented to our emergency department with severe stridor and respiratory distress. He was admitted in intensive care, attempted Montgomery T tube insertion by ENT surgeon but respiratory distress persisted. Hence patient was intubated again. Bronchoscopy was performed and visualised the subglottic stenosis (Fig. 1).

Although surgical resection and anastomosis is definitive treatment, however considering the underlying neurological condition of patient, relatives opted for silicone stenting. Repeat check bronchoscopy performed and measured

the stenosed segment. The sub glottic stenotic segment was 25 mm length. We performed rigid bronchoscopy and put silicone stenting in the stenosed subglottic segment (Fig. 2).

Post silicone stenting, patient's stridor resolved, respiration and breathing efforts became stable. Patient is on regular follow up and position of stent had been confirmed after one month. Patient is having stent in situ for last 1.5 years, and check bronchoscopies performed serially to rule out infection and stent migration.

2.2 Case 2

17 year old male, admitted with stridor and respiratory distress. He had a history of consuming organo phosphorous poisoning one month back, and was intubated for 15 days.

On examination, his pulse rate was 124 beats per minute, blood pressure 120/70 mm Hg, respiratory rate 24 breaths per minute, and spo2 90 % room air. He was given nebulisations with bronchodilators and taken up for bronchoscopy. There was multiple level tracheal strictures seen starting from around 2-3 cm below the vocal cords, and extending for 6 -7 cm below the vocal cord, and extending for 6-7 cm length upto mid trachea, bronchoscope was not passing below the level of obstruction (Fig. 3). Argon plasma coagulation done under vision, followed by balloon dilatation, and tracheal lumen increased upto 50% of total diameter. Bronchoscope could be passed distally (Fig. 4). Distal trachea was normal. We advised silicone stenting of airway as a permanent solution, which they were not willing. Patient is managing well on follow up.

2.3 Case 3

33 year old female, presented to pulmonology out-patient department with complaints of breathlessness on exertion, Modified Medical Research Council grade 3. She had history of pulmonary tuberculosis 5 years back, for which 6 months complete anti-tubercular treatment taken. On examination, her vitals were stable. Patient's spirometry showed moderate to severe obstruction with no reversibility. Her chest radiograph showed complete collapse of left lung (Fig. 5). HRCT thorax showed complete collapse of left lung with compensatory hyper inflation of right lung (Fig. 6).

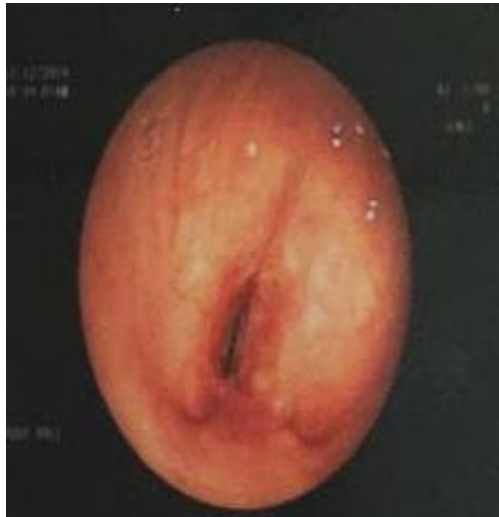


Fig. 1. Subglottic stenosis visualised by bronchoscopy of CASE 1 patient

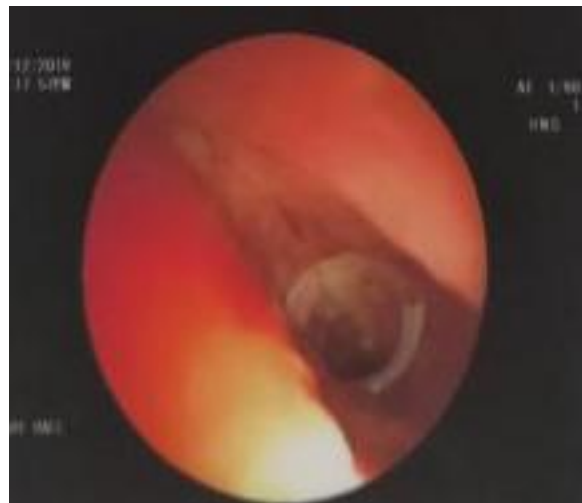


Fig. 2. Silicone Stenting insitu in CASE 1

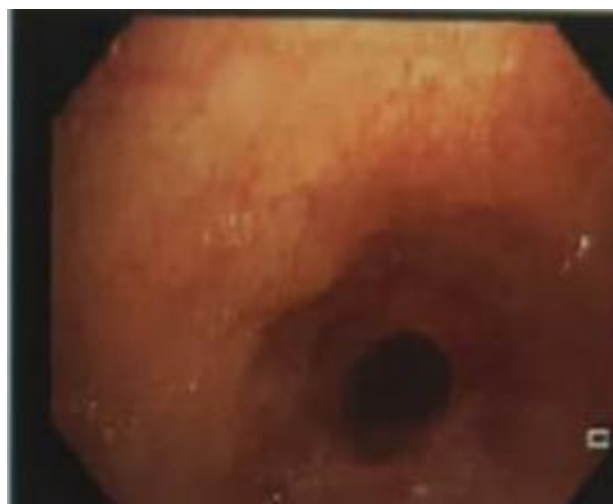


Fig. 3. The subglottic stenosis visualised by bronchoscopy in case 2

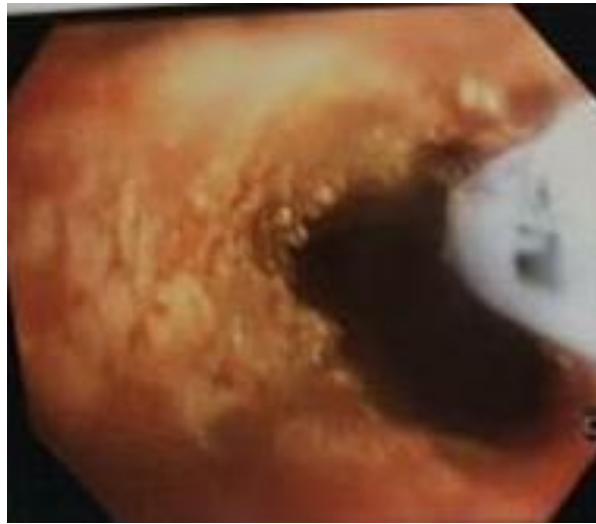


Fig. 4. Dilated airway following Argon plasma coagulation and balloon dilatation

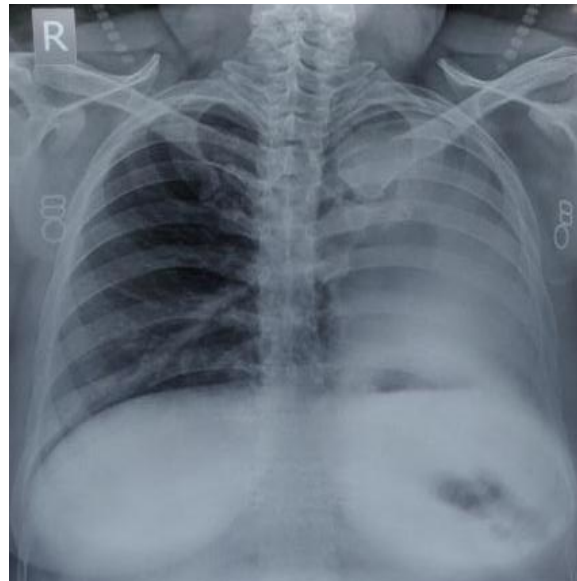


Fig. 5. Chest radiograph showing complete collapse of left lung

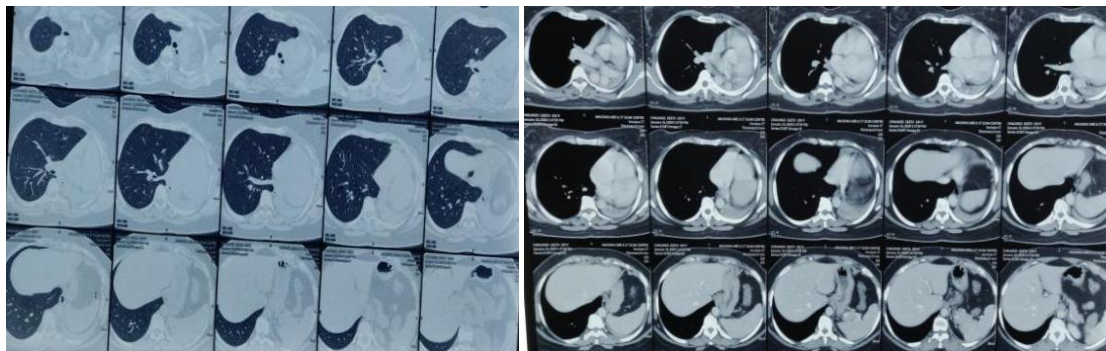


Fig. 6. HRCT thorax showed complete collapse of left lung with compensatory hyper inflation of right lung

As the patient is young and symptomatic, we performed bronchoscopy and visualised the complete obstruction of left main bronchus and a small mucosal pit at the opening of left main bronchus (Fig. 7).

Guide wire was passed initially, then argon plasma coagulation done followed by balloon dilatation. Bronchus opened up (Fig. 8), and post procedure chest radiograph showed that the lungs are opened (Fig. 9) and patient became symptomatically better.

2.4 Case 4

78 year old female came to pulmonology out patient department with history of breathlessness on exertion for 2 months, Modified medical research council grade 2. She had a history of childhood tuberculosis for which complete treatment had been taken.

Patient had similar history 8 months for which she was evaluated.

Her sputum gene expert was positive for tuberculosis with rifampicin sensitivity. She had taken 6 months course of anti tubercular treatment and stopped 2 months back.

She has underlying diabetes, hypertension and ischemic heart disease.

On examination, her vitals were stable.

Her chest radiograph showed complete collapse of left lung (Fig. 10) while her chest radiograph 6 months back were normal.

HRCT thorax showed collapse of left lung with compensatory hyperinflation of right lung.

Bronchoscopy done and visualised complete obstruction of left main bronchus, and even passing guidewire was not possible.

The option for rigid bronchoscopic dilatation and stenting was given. However considering her age and co-morbidities, patient opted for conservative management. On follow up, patient is stable vitally.

3. DISCUSSION

3.1 Clinical Discussion

Tracheo bronchial stenosis can occur congenitally or acquired. Most cases of tracheal stenosis develop as a result of prolonged breathing assistance known as intubation or from a surgical tracheostomy. The tracheal stenosis can also occur following infection like tuberculosis, trauma to airway, malignancy, granulomatous diseases like Wegener's granulomatosis. The symptoms include wheezing, stridor, chest congestion, recurrent pneumonia [3].

3.2 Imaging Discussion

On chest radiograph and HRCT thorax, eccentric or concentric soft tissue thickening internal to normal-appearing tracheal cartilage may be visible. The outer tracheal wall has a normal appearance without evidence of deformity or narrowing. Expiratory CT shows little change in tracheal diameter [4].

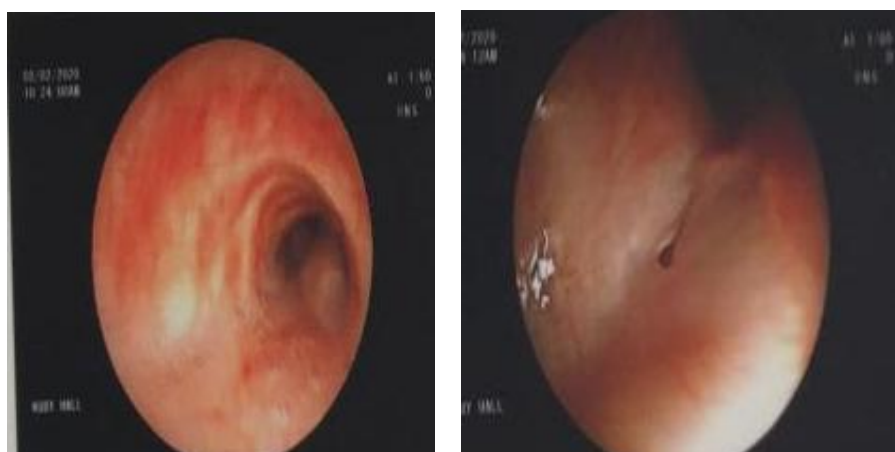


Fig. 7. Bronchoscopy showing the completely obstructed left main bronchus, even passing the guidewire is not possible

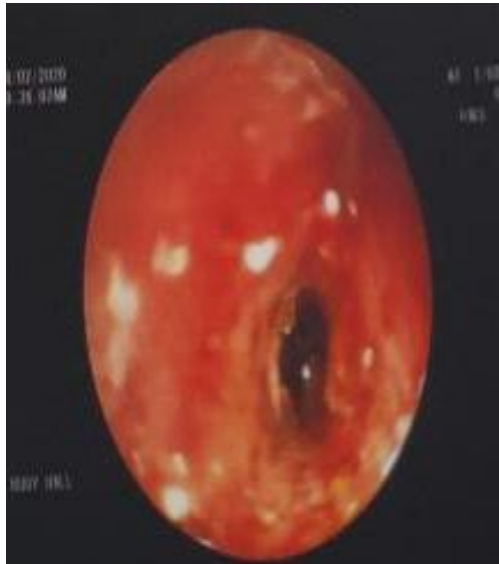


Fig. 8. The bronchus open up on the left side post dilatation

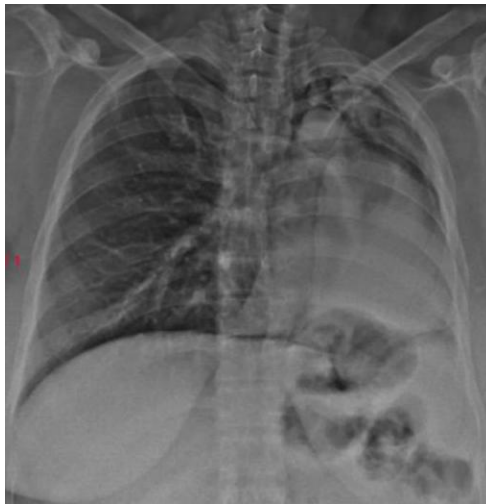

Fig. 9. The chest radiograph post procedure shows the expanding lung

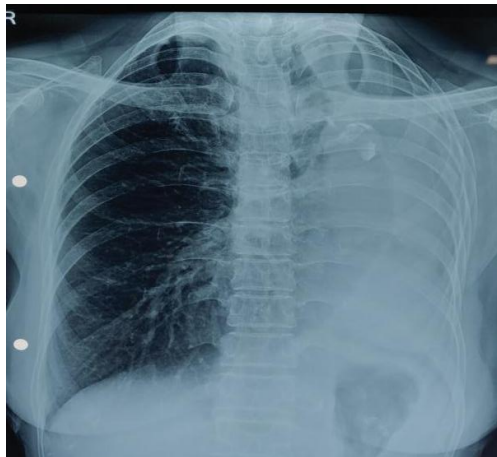


Fig. 10. Chest radiograph showing left lung collapse

3.3 Management

The trachea-bronchial stenosis can be managed by surgical resection and anastomosis, tracheo-bronchial laser surgery, tracheal dilatation and tracheal stent [5]. The short term treatment options are laser surgery and dilatation, but the long term treatment option with a promising outcome is surgical resection and anastomosis [3]. Patients who require more than one session of balloon dilatation may need more definitive treatment such as stenting or ablative procedures [6,7].

The airway trauma related to intubation is most common cause of tracheal stenosis [1]. The most common reason is intubation-related trauma [1,8], and the incidence of glottic stenosis related to intubation trauma varies from 4% to 14% [1,9]. Mucosal injuries during intubation at the level of glottis commonly occur at the medial surface of vocal process of arytenoids and interarytenoid region [1,10].

In endobronchial tuberculosis, left bronchial involvement is seen more frequently than right bronchial or tracheal involvement [2,11]. It is postulated that the left mainstem bronchus is anatomically compressed by the aortic arch and the left mediastinal lymph nodes tend to get infected faster than the right sided lymph nodes, resulting in increased vulnerability of the left main stem bronchial stenosis.

The treatment for airway stenosis due to tuberculosis is to control infection by adequate anti-tubercular treatment, steroids, bronchoscopic methods like Argon plasma coagulation, balloon dilatation and stenting may be required as per the clinical scenario [2].

From our experience of managing the airway stenosis, there should be a personalised approach for each patient.

The 2 cases of post tubercular bronchial stenosis were treated in 2 different ways - the elderly lady with co-morbidities was treated with conservative medical management while young lady with no co-morbidities was treated with Argon plasma coagulation and balloon dilatation.

The 2 cases of post intubation tracheal stenosis were managed in different ways - one case with silicone stenting, the other with Argon plasma coagulation and balloon dilatation.

4. CONCLUSION

The management of airway stenosis is complicated and it requires categorising the patient according to their co-morbidities, activities of daily living and personalising the approach.

The patients with no co-morbidities, young age should be given an option for surgical resection and anastomosis or silicone stenting as this increases the quality of life.

The article emphasizes on personalizing the approach towards airway stenosis management for a better outcome and prognosis for the patient. We recommend argon plasma coagulation and balloon dilatation for temporary management and airway stenting for a permanent solution for the airway stenosis.

CONSENT

Case report has been written after taking an informed consent from patients.

ETHICS APPROVAL

The case report was an observational study and hence ethics committee approval has been waived off.

COMPETING INTERESTS

Authors have declared that no competing interests exist.

REFERENCES

1. Gyawali BR, Pradhananga RB, Acharya K, Dutta H, Neupane Y, Baskota DK, et al. Aetiopathogenesis of laryngotracheal stenosis: A retrospective review. *Int J Otolaryngol* [Internet]. 2020;2020:1–6. Available: <http://dx.doi.org/10.1155/2020/1941046>
2. Pathak V, Shepherd RW, Shojaee S. Tracheobronchial tuberculosis. *J Thorac Dis* [Internet]. 2016;8(12):3818–25. Available: <http://dx.doi.org/10.21037/jtd.2016.12.75>
3. Tracheal stenosis [Internet]. Cedars-Sinai; 2022. [cited 2022 Feb 12]. Available: <https://www.cedars-sinai.org/health-library/diseases-and-conditions/t/tracheal-stenosis.html>

4. Di Muzio B, The Radswiki. Tracheal stenosis. In: Radiopaedia.org. Radiopaedia.org; 2011.
5. Tracheal Stenosis [Internet]. Mount Sinai Health System; 2022. [cited 2022 Feb 12]. Available: <https://www.mountsinai.org/care/ent/services/tracheal-surgery/tracheal-stenosis>
6. Shitrit D, Kuchuk M, Zismanov V, Rahman NA, Amital A, Kramer MR. Bronchoscopic balloon dilatation of tracheobronchial stenosis: Long-term follow-up. *Eur J Cardiothorac Surg* [Internet]. 2010;38(2):198–202. Available: <http://dx.doi.org/10.1016/j.ejcts.2009.11.056>
7. Faisal M, Harun H, Hassan TM, Ban AYL, Chotirmall SH, Abdul Rahaman JA. Treatment of multiple-level tracheobronchial stenosis secondary to endobronchial tuberculosis using bronchoscopic balloon dilatation with topical mitomycin-C. *BMC Pulm Med* [Internet]. 2016;16(1):53. Available: <http://dx.doi.org/10.1186/s12890-016-0209-1>
8. Stephenson KA, Wyatt ME. Glottic stenosis. *Semin Pediatr Surg* [Internet]. 2016;25(3):132–7. Available: <http://dx.doi.org/10.1053/j.sempe dsurg.2016.02.003>
9. Howard NS, Shiba TL, Pesce JE, Chhetri DK. Photodocumentation of the development of type I posterior glottic stenosis after intubation injury. *Case Rep Surg* [Internet]. 2015;2015:504791. Available <http://dx.doi.org/10.1155/2015/504791>
10. Benjamin B, Holinger LD. Laryngeal complications of endotracheal intubation. *Annals of Otology, Rhinology & Laryngology*. 2008;117(9):1–20.
11. Lee JH, Turk SS, Lee DH, Shin DH, Yang SC, Yoo BM. Endobronchial tuberculosis. *Chest* [Internet]. 1992;102(4):990–4. Available: <http://dx.doi.org/10.1378/chest.102.4.990>

© 2022 Modi and Devi; This is an Open Access article distributed under the terms of the Creative Commons Attribution License (<http://creativecommons.org/licenses/by/4.0>), which permits unrestricted use, distribution, and reproduction in any medium, provided the original work is properly cited.

Peer-review history:

The peer review history for this paper can be accessed here:

<https://www.sdiarticle5.com/review-history/82456>