



Obstetrical Management of Dystocia Due to Uterine Torsion and Faulty Disposition of Foetus in Banni Buffalo

Ravindra Jadav ^{a*}, Sachin Kalaswa ^a, Keshav ^b,
Janak Panchal ^a, Vipul Solanki ^a, H. C. Nakhshi ^a
and B. N. Suthar ^a

^a Department of Veterinary Gynaecology and Obstetrics, College of Veterinary Science and Animal Husbandry, Sardarkrushinagar, Dantiwada, Kamdhenu University, Gujarat, India.

^b Department of Animal Reproduction, Gynaecology and Obstetrics, Assam Agricultural University, Khanapara, Guwahati, Assam, India.

Authors' contributions

This work was carried out in collaboration among all authors. All authors read and approved the final manuscript.

Article Information

DOI: 10.9734/IJBCRR/2024/v33i5876

Open Peer Review History:

This journal follows the Advanced Open Peer Review policy. Identity of the Reviewers, Editor(s) and additional Reviewers, peer review comments, different versions of the manuscript, comments of the editors, etc are available here: <https://www.sdiarticle5.com/review-history/115238>

Case Study

Received: 13/02/2024
Accepted: 17/04/2024
Published: 19/04/2024

ABSTRACT

A Banni buffalo in 3rd parity was presented with the history of completed gestation period and violent straining for more than forty eight hours without any progress in calving. On per-vaginum and per-rectum revealed dystocia due to 180° post-cervical right sided uterine torsion. Caudal epidural anesthesia was applied by injecting 5 ml of 2% lignocaine and the animal was calmed down with 0.2 ml xylazine (IV) and cast on the side of torsion because highly furious and uncontrol or unable to restrained, then the rolling was applied as described by Modified Schaffer's detorsion method. After second roll the torsion was completely corrected. A dead male fetus was delivered by close critical obstetrical management with therapeutically using intravenous administration of 10ml-

*Corresponding author: E-mail: rjadav31@gmail.com;

Dexamethasone®, 75IU-Oxytocin®, 1litre-Normal saline, 1litre Ringer lactate and 200ml-Calcium magnesium borogluconate, whereas 10ml-Valethamate bromide (Epidosin®) was given intramuscularly result into completely opened and dilatation of cervix in buffalo. Then the buffalo was post-medicated with various fluids, analgesic, antibiotic and antihistamine parentally apart from intra-uterine passaries which resulted to normal health of affected Banni buffalo.

Keywords: Banni buffalo; dystocia; modified schaffer's method and uterine torsion.

1. INTRODUCTION

Uterine torsion is the rotation of the gravid horn around its long axis [1] which leads to narrowing of the birth canal causing dystocia. "Torsion of the gravid uterus in bovine is a common condition encountered by the field veterinarians and has been reported to be one of the major causes of dystocia" [2,3]. "Uterine torsion is commonly observed in buffaloes, dairy cows and occasionally in beef cows" [4]. "Cows and buffaloes are thought to be more susceptible to uterine torsion due to uterine instability resulting from dorsolateral attachments of broad ligament. Although the process of parturition in cattle and buffalo appears to be similar, but subtle differences are known to be existent in the anatomy and physiology of the birth canal between cows and buffaloes" [5]. "As such the incidence of uterine torsion is considered to be higher in buffaloes compared to cows" [6]. "In majority of cases the pregnant uterus rotates about its long axis, with the point of torsion being the anterior vagina just caudal to the cervix. This is the post-cervical torsion. For the treatment of uterine torsion cases, either of the techniques is being used: per-vaginal rotation of fetus or modified Schaffer's detorsion method with rolling of dam. The management option needs to be selected judiciously on the basis of the feasibility of the technique" [7].

2. CASE PRESENTATION

2.1 History and Clinical Observations

An eight years old Banni buffalo with its 3rd parity was presented to the Animal Obstetrics unit of Dr. V. M. Jhala Clinical Complex with the history of complete gestation, water bag was not ruptured, and straining, restlessness and tenesmus since last more than two days, without any progress in parturition. Physiological parameters recorded were in the slightly elevated to normal clinical range; temperature (103.1°F), respiration rate (36/minute) and while heart rate (88/minute/ slightly tachycardia). Clinical symptoms include the buffalo was partial anorexic since two days, non progressive labor,

discomfort, colic signs, anorexia, impaction of rumen, arched back and slightly dehydrated with standing condition. The buffalo was frequently getting up and down showing extreme abdominal pain. Also the histories of owner in form of uterine torsion diagnosed by local field veterinary officer with three rotations were given at home but not any improvement was observed. Clinical observation revealed that the pelvis normal, pelvic ligaments were not relaxed, valva & valval lips were slight oedematous with mild twisted at right side, conjunctival (Fig. 1) and vaginal (Fig. 2) mucous membranes membrane were slightly congested, mammary glands fully engorged with milk (Fig. 3) and fowl smelling dark reddish abnormal bloody vaginal discharged was observed (Fig. 4). "On proper lubrication (liquid paraffin) per-vaginal examination revealed that the slight right sided spiraling tilt of the anterior/ cranial part of vagina, uterine dark reddish abnormal fowl smelling discharges was observed, vagina was relaxed, slightly twisted vaginal fold was palpated going toward right side lateral downward and forward, direction of the twist towards the right side, site of twist at post cervical and approximately two to three finger opened. On proper lubrication (liquid paraffin) per-rectal examination revealed that the broad ligament of left side is stretched (extending toward the right side (right side broad ligament sinking beneath the uterus), uterine surface was tense with thick walled, fremitus was absent, foetus was palpated but motility was absent, complete one uterine fold was palpated and the arrangement of broad ligaments with the spiral twist in the uterus just post-caudal to the cervix that could be appreciated upon rectal examination was suggestive of left sided post-cervical uterine torsion of over 180°" [8]. Based on the history, a clinical sings, per-vaginal and per-rectal examination the case was diagnosed as post-cervical right side uterine torsion of about 180° dystocia.

2.2 Obstetrical and Therapeutic Management

The caudal epidural anesthesia was applied by injecting 5 ml of 2% lignocaine hydrochloride®

and the animal was calmed down with 0.2 ml xylazine® (IV) and cast on the side of torsion because highly furious and uncontrol or unable to restrained large sized Banni buffalo, then the detorsion was attempted by rolling the animal using modified Schaffer's method after casting on its right side lateral recumbency in the direction of torsion and the front and hind legs were tied secured separately ((Fig. 5 and Fig. 6) and uterine torsion was corrected. Dam rotated to the same degree and direction to which the uterus has rotated, keeping the fetus fixed by fixing uterus with a wooden plank (length: 10 feet, width: 1 feet and thickness: 1 inch) or Modified Schaffer's method [7]. The wooden plank was placed on the upper paralumbar fossa of dam in an inclined manner with lower end on ground (Fig. 7). "The animal

was rolled over on to its back, the front and hind legs were pulled up and over the recumbent dam. While rolling, wooden plank was anchored by 1-2 medium weight assistants who stood still upon the lower end of wooden plank and another assistant moved on the plank. An additional assistant modulated the pressure on the plank by pressing the upper end of plank. After each roll, effectiveness of roll was judged by transvaginal examination" [9]. In this case two rotation were given in clockwise (Fig. 8, right side) direction by using Modified Schaffer's method and improvement was observed in form of disappearance of the vaginal spirals or rectal pouch could be immediately palpated and a gush of large quantity discharge appeared through the vagina.

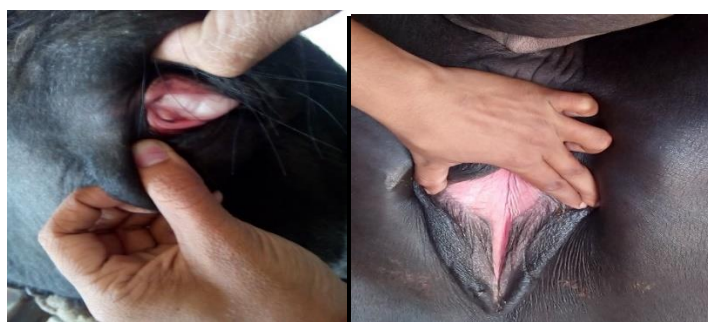


Fig. 1 & 2. Conjunctival and Vaginal mucous membrane were slightly congested



Fig. 3. Mammary glands fully engorged with milk

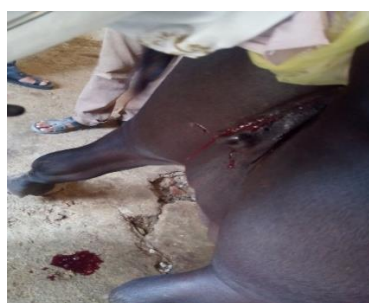

Fig. 4. Dark reddish bloody discharge come out from vagina and twisted valva toward right side



Fig. 5. Restraining the buffalo by holding fore limbs and hind limbs of buffalo



Fig. 6. Restraining the buffalo in right lateral recumbency



Fig. 7. Placing the plank over the abdomen



Fig. 8. Rotation of animal in clock wise direction



Fig. 9. Buffalo was pre-medicated treatment

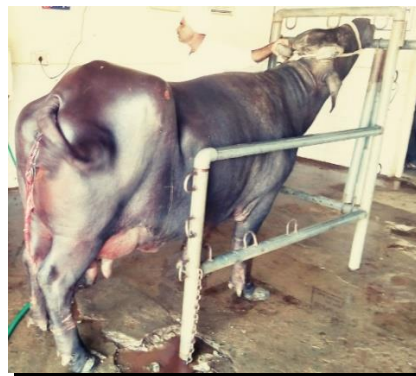

Fig. 10. fetal allantoic bag ruptured membrane & fowl smelling turbid fluid where observed



Fig. 11. Vaginal delivery of dead fetus by Equal force extraction should be applied to each rope and obstetrical hooks on forelimbs & head from birth canal of dam



Fig. 12. Delivered large size male fetus

On proper lubrication (liquid paraffin) and proper antiseptic precaution (1% potassium permanganate lotion) per-vaginal examination revealed that the torsion was completely relieved, vaginal dark reddish fowl smelling bloody discharged was observed, cervix was five fingers dilated but foetus have not any movement., water bag was not ruptured, fetus forelimbs was palpated, but not able to deliver calf due to not available of proper space for force extraction of fetus. So decided that the buffalo was pre-medicated (Fig. 9) with intravenous administration of 10ml Dexamethasone®, 1litre Normal saline, 1litre Ringer lactate, 75IU-Oxytocin® and 200ml Calcium magnesium borogluconate, Whereas 10ml Valethamate bromide (Epidosin®) was given intramuscularly. Completion of pre-medicinal treatment after three hours the fetal allantoic bag ruptured (false water bag) with fowl smelling turbid fluid come out from vagina (Fig. 10), then again with proper lubrication and proper antiseptic precaution per-vaginal examination revealed that the cervix was completely dilated the palpated fetus in posterior longitudinal presentation, dorso-iliac position, with lateral deviation of the head, bilateral carpal flexion and both fore limbs were retained beneath to the foetus body. Following confirmatory diagnosis of dystocia due to fetal malposition and malpostures, after the careful repelling of the foetus into abdominal cavity of dam, then after proper lubrication of the birth canal using liquid paraffin and rinsing the perianal region with the 1% potassium permanganate lotion, an attempts were made to per-vaginal to withdrawal fetus (Fig. 12) from uterus to birth canal of the dam by manually followed by application of obstetrical hooks in inner-canthus of eyeball, application of snares with complete tied to both the forelimbs and lower jaw separately than dead fetus was delivered by forced extraction. The buffalo got up by herself within 15 minutes after the dead large size male fetus was delivered. Buffalo was post-medicated (Fig. 7) with intramuscularly administration 10 ml-Chlorpheniramine maleate® (Antihistamines), 10ml-Vitamin B-complex Injection, Melonex® (Meloxicam-Intas, India) @ 0.5mg/kg. b.wt. IM OD and Quintas® (Enrofloxacin-Intas, India) @ 5mg/kg. B.wt. IM OD; whereas 1litre Dextrose normal saline (5%DNS) was given intravenously. "The Liquid Exapar® (Indigenous herbal uterine cleanser and restorative-Natural Remedies, India) @ 50 ml twice PO and liquid Gluca-boost (To maintain the energy/glucose-Natural Remedies, India) @ 200ml once PO, antibiotic, analgesic and

antihistamine intramuscularly treatment was continued for 7 days. Information of the patient was taken telephonically every alternate day following discharge from hospital. The buffalo was found active and alert resuming normal appetite within a few days post treatment. Eventually, the buffalo recovered uneventfully" [9].

3. DISCUSSION

In this case post-cervical right side 180° uterine torsion observed with faulty fetal disposition was corroborate with Sloss and Dufty, [10] in buffaloes. Drost, [11] indicate that the "as pregnancy advances, the broad ligaments do not extend proportionately with the gravid uterus, leading to instability of uterus". Singh et al. [12] and Jayakumar et al. [13] suggest that "the increased fetal movements during labor may be a precipitating parturient factor, Other such factors that have been mentioned are: decreased amount of uterine fluid, flaccid uterine wall, small non gravid horn, excess fetal weight, also the bovine amnion is fused at many places to the surrounding allantois, which is attached to the uterine wall". Mannari and Tadmok, [14] reported that "the rotatory fetal movements during the second stage of labor or late gestation would rotate the uterus along with it resulting in uterine torsion, a large number of predisposing causes have been described for uterine torsion in cows and buffaloes which include besides anatomical factors, close confinement, hilly tracts, and wallowing habits of the buffaloes, the resting of bovines on their knees for a while when getting up and the lowering of front legs by the animal first, when lying down have also been suggested as one of the causes". Purohit et al. [6] described "the Some exciting causes for the occurrence of uterine torsion have also been include external injury, lack of exercise and irregular movement of animals, slight rotations (below 90°) are symptom less clinically and may be corrected spontaneously during parturition, but rotations of higher degree usually do not detort by themselves and need Clinician's attention, also the incidence of uterine torsion is considered to be higher in buffaloes compared to cows", Prasad et al. [15] and Aubry et al. [16] reported "incidence of right sided torsion is 90% in *Bubalus bubalis buffaloes* with Incidence of post-cervical torsions is 66- 96%, all are above observations similar which were might have been close agreement with present case report".

4. CONCLUSION

The Banni buffalo was diagnosed with dystocia due to uterine torsion and incorrect foetal disposition. The buffalo was saved from certain death by prompt intervention using a modified Schaffer's detorsion method along with subsequent medical therapy, which resulted in the delivery of a dead male foetus.

ETHICAL APPROVAL

As per international standards or university standards written ethical approval has been collected and preserved by the author(s).

COMPETING INTERESTS

Authors have declared that no competing interests exist.

REFERENCES

1. Rakuljic-Zelov S. Haematological and biochemical profile of cows affected with uterine torsion. *Slovenian Veterinary Research*. 2002;39(1):1580–4003.
2. Pearson H. Uterine torsion in cattle: A review of 168 cases. *Veterinary Record*. 1971;89(23):597-603.
3. Singh VK, Sharma RD, Dhaliwal GS, Gandotra VK, Prabhakar S. Uterine torsion in cows- and analysis of 34 cases. *Indian Veterinary Journal*. 1992;69:281-282.
4. Sheetal SK, Prasad S, Gupta HP. Clinical management of pre-partum uterine torsion and cervico vaginal prolapse in a cow. *Intas Polivet*. 2014;15(II):248-249.
5. Kodagali SB. Notes on applied bovine reproduction. Part II. In: Kodagali S.B. Ed., *Bovine Obstetrics*. Indian Society for the study of Animal Reproduction Gujarat Chapter Anand, Gujarat, India. 2003; 22-67.
6. Purohit GN, Barolia Y, Shakher C, Kumar P. Maternal dystocia in cows and buffaloes: A review. *Open Journal of Animal Sciences*. 2011;1(II):41-53.
7. Ghuman SPS. Uterine torsion in bovines: A review. *Indian Journal of Animal Science*. 2010;80:289-05.
8. Assad NI, Ahmad R, Ashraf A. Successful clinical management of dystocia due to pre-cervical uterine torsion in a crossbred holstein friesian cow: A case report. *Theriogenology Insight-An International Journal of Reproduction in all Animals*. 2015;5(3):183-90.
9. Kalaswa SM. 3. Non-surgical management of dystocia due to uterine torsion in a mehsana buffalo by sm kalaswa, tv sutaria, hc nakhashi, bn suthar, vl solanki, hk thumar and mr patel. *Life Sciences Leaflets*. 2018 Oct 1;104:20-to.
10. Sloss V, Dufty JH. Distocia. In *handbook of bovine obstetrics*, baltimore; London: Williams and wilkins. 1980;108-111.
11. Drost M. Complications during gestation in cow. *Theriogenology*, 2007;68:487-491.
12. Singh P, Prabhakar S, Kochar HP. Uterus didelphus: A cause of torsion of uterus in a buffalo. *Indian Veterinary Journal*. 1995;72:172-173.
13. Jayakumar C, Sudha G, Lakshmikanth TR, Kantharaj S. Uterine torsion in cattle: A study of 16 referral cases. *Intas Polivet*. 2014;15(11):228-232.
14. Mannari MN, Tadmok DM. Uterine torsion in buffaloes. *Indian Journal of Animal Sciences*. 1976;10:83.
15. Prasad S, Rohit K, Maurya SN. Efficacy of laparohysterotomy and rolling of dam to treat uterine torsion in buffaloes. *Indian Veterinary Journal*. 2000;77:784-786.
16. Aubry P, Warnick LD, DesCôteaux L, Bouchard É. A study of 55 field cases of uterine torsion in dairy cattle. *Canadian Veterinary Journal*. 2008;49(4):366-372.

© Copyright (2024): Author(s). The licensee is the journal publisher. This is an Open Access article distributed under the terms of the Creative Commons Attribution License (<http://creativecommons.org/licenses/by/4.0>), which permits unrestricted use, distribution, and reproduction in any medium, provided the original work is properly cited.

Peer-review history:

The peer review history for this paper can be accessed here:
<https://www.sdiarticle5.com/review-history/115238>